Reliability of IOTA score and ADNEX model in the screening of ovarian malignancy in postmenopausal women

Erdogan Nohuz, Luisa de Simone, Gautier Chêne

Reliability of IOTA score and ADNEX model in the screening of ovarian malignancy in postmenopausal women

Dr Erdogan Nohuz -- Service de Gynécologie-Obstétrique, Centre hospitalier de Thiers --- Route de Fau, 63300 Thiers, France ---- enohuz@yahoo.fr

Abstract

Background

The IOTA (International Ovarian Tumour Analysis) group has developed the ADNEX (Assessment of Different NEoplasias in the adneXa) model to predict the risk that an ovarian mass is benign, borderline or malignant. This study aimed to test reliability of these risks prediction models to improve the performance of pelvic ultrasound and discriminate between benign and malignant cysts.

Material and methods

Postmenopausal women with an adnexal mass (including ovarian, para-ovarian and tubal) and who underwent a standardized ultrasound examination before surgery were included. Prospectively and retrospectively collected data and ultrasound appearances of the tumours were described using the terms and definitions of the IOTA group and tested in accordance with the ADNEX model and were compared to the final histological diagnosis.

Results

Of the 107 menopausal patients recruited between 2011 and 2016, 14 were excluded (incomplete inclusion criteria). Thus, 93 patients constituted a cohort in whom 89 had benign cysts (83 ovarian and 6 tubal or para-ovarian cysts), 1 had border line tumor and 3 had invasive ovarian cancers (1 at first stage, 1 at advanced stage and 1 metastatic tumour in the ovary). The overall prevalence of malignancy was 4.3%. Every benign ovarian cyst was classified as probably benign by IOTA score which showed also a high specificity with the

totality of probably malignant lesion proved malignant by histological exam. The limit of this score was the important rate of not classified or undetermined cysts. However, the malignancy risks calculated by ADNEX model a lowed identifying the totality of malignancy. Thus, the combination of the two methods of analysis showed a sensitivity and specificity rates of respectively 100% and 98%. Evaluation of malignancy risks by these 2 tests highlighted a negative predictive value of 100% (there was no case of false negative) and a positive predictive value of 80%.

Discussion and conclusion

On the basis of our findings, the IOTA classification and the ADNEX multimodal algorithm used as risks prediction models can improve the performance of pelvic ultrasound and discriminate between benign and malignant cysts in postmenopausal women, especially for undetermined lesions.

Keywords

Ovarian cancer; Adnexal mass; Ultrasonography; IOTA score; ADNEX model

1. Introduction

Pelvic ultrasound in menopausal women can often visualize an adnexal mass which represents a common gynaecological disorder whose preoperative characterization is of crucial importance for an optimal management strategy [1]. Physician's challenge, once he's confronted to this situation, is to establish the malignancy risk insofar as ovarian cancer is the most aggressive gynecological malignancy. Indeed, the five years survival rate of patients is around 40% and the disease accounts for approximately half of all deaths related to gynecological cancer [2,3]. Several arguments promote further research on ovarian cancer screening. This pathology has all of screening eligibility features (high prevalence, high mortality due to late diagnosis, presence of a detectable and curable preclinical stage).

Moreover, the most important factor for survival is stage at diagnosis and nowadays there isn't a proven effective screening strategy. Statistics results found an increased risk among postmenopausal women [4-7]. It is necessary to identify the best tool to detect early stage disease. Ultrasound' role in cancer screening, as first line medical exam in case of ovarian mass, isn't validated. Correct interpretation of the images is mandatory to attempt the diagnosis. In case of benign cyst, surgery can be avoided whereas the failure to take in account a malignant or borderline lesion can be deleterious and may lead to compromise patients' survival [8].

Prediction models have been developed to assist clinicians to determine the malignancy risk of ovarian cyst and decide the appropriate treatment pathways avoiding possible mistakes. They require an accurate description of the ultrasound image in order to characterize it as well as possible: lesion' size, unilocular or multilocular appearance, smooth tumor, presence of papillary projections and / or solid components and / or acoustic shadow, Doppler score and association with ascites. The IOTA group (International Ovarian Tumor Analysis) developed clinically useful ultrasound criteria that can be used to classify most adnexal masses as probably benign or probably malignant: the IOTA classification based on ten ultrasound simple rules published by Timmerman in 2008 and validated by several other studies [9-12]. In order to improve test' performance, multimodal prediction models incorporate to sonographic scoring system the serum CA 125 level and anamnestic information as the menopausal status.

Several multimodal prediction models are actually available as the RMI (Risk of Malignancy Index) of the Royal College of Obstetrics and Gynaecology, the logistic regression models (LR1 and LR2) or the ADNEX (Assessment of Different NEoplasias in the adneXa) model of the IOTA group [13-17]. Comparative essays prove better predictive performance of logistic regression model as the risk malignancy index because of the addition of Doppler parameters

[18]. The ADNEX model predicts the type of malignancy in addition to offering discrimination between benign and malignant tumors. However, its superiority compared to other algorithms remains to be proven [19]. Knowledge of the specific type of adnexal pathology before surgery is likely to improve patient triage with a high accuracy, and it also makes it possible to optimize treatment [17]. The correct identification of stage I cancer is particularly important [20].

Most prediction models have been developed on series of patients with adnexal mass requiring surgery. Neither the logistic regression model nor the ADNEX model can replace training and experience in ultrasonography [21]. The French College of Obstetrics and Gynaecologists (CNGOF) recommendations advocate the transvaginal pelvic ultrasound as the first-line imaging examination for presumed benign ovarian tumors in adult women [22]. Surgical treatment is recommended in case of organic cyst or when changes affect the volume and morphology of a cyst of functional appearance. Doppler score is recognized as the best predictive parameter. On the other hand, for the CNGOF, the role of multimodality prediction algorithms in diagnosis of ovarian malignancy isn't determined. Abstention can be an option in adult women with a probably benign cyst presenting as unilocular asymptomatic anechoic mass smaller than 10 cm and no history of cancer [22].

In this study, we aimed to test the IOTA rules and ADNEX model as prediction models used to discriminate between benign and malignant cysts in a postmenopausal population.

2. Patients and Methods

We carried out a monocentric observational retrospective study on a cohort of postmenopausal patients who underwent surgery for adnexal mass between January 2011 and March 2016. The setting was our obstetrics and gynaecological surgery unit (Thiers' Hospital, located at Auvergne-Rhône-Alpes Region, France). The surgical indication was based on the

clinical context of the adnexal mass' discovery by transvaginal ultrasound exam and the subjective assessment of the ultrasound images. The necessary condition for eligibility was the presence of transvaginal ultrasound picture. Data collected by examining the medicals records were stored on a table created with Microsoft Excel® software. All patients underwent a serum CA-125 level. However, after 2014, the combined blood determination of CA-125 and HE4 (Human Epididymis Protein 4) to establish the ROMA (Risk of Ovarian Malignancy Algorithm) algorithm was performed. Indeed, HE4 used in conjunction with CA 125 as serum tumor biomarker seems to have a higher predictive performance for ovarian cancer compared with the use of CA 125 alone [23]. We applied the 10 ten simple rules of IOTA score to all ultrasound cyst images in order to classify the lesion in probably benign (B), probably malignant (M) or undetermined. IOTA classification's norms allowed characterization of the adnexal mass. If one or more M-rules have been applied in the absence of a B-rule, the mass was classified as malignant. If one or more B-rules have been applied in the absence of a M-rule, the mass was classified as benign. If both M-rules and B-rules or no rule have been applied, the mass could not be classified. For not classified masses, we calculated the risk of malignancy with ADNEX model online algorithm (http://www.iotagroup.org/adnexmodel/site%20iota.html). The threshold chosen was 10% as recommended by clinical trials for patients over 43 years old [24]. The reference standard was the histopathological diagnosis of the mass after surgical removal by laparoscopy or laparotomy considered appropriate by the surgical team. The stage of malignant tumors was established using the classification of the International Federation of Gynecology and Obstetrics (FIGO) [25]. Histological classification was performed without knowledge of the ultrasound results. The final diagnosis was divided into five tumor types: benign, borderline, stage I invasive, stage II-IV invasive, and secondary metastatic cancer.

We investigated the diagnostic performance of the two methods (10 IOTA simple rules and

ADNEX model), i.e. sensitivity, specificity, positive likelihood ratio (LR+) and negative likelihood ratio (LR−). The ten simple rules IOTA score system was tested to all adnexal masses of the trial series. This method had been chosen because it's strictly ultrasound based and it don't need other exam so the result is quickly available. ADNEX model was also applied in case of not classified cyst after IOTA score test. This model has a capacity in well differentiating benignant and malignant tumors and offering plenty of information concerning the tumor (not only the malignancy risk) [11]. Thus, ADNEX model was used as a second stage test in case of doubtful ultrasound diagnosis [26]. Screening performance of the 2 tests were evaluated in association. To do this, benign matched tests were considered as negative, malignant matched tests were considered as positive: non-conclusive IOTA scores with ADNEX model at low-risk were considered as negative while at high-risk were considered as positive.

3. Results

The cohort of patients was made of 107 menopausal women of whom 14 were excluded: 6 based on exclusion criteria (premenopausal women), 8 because of data errors or uncertain or missing final histology and ultrasound images. The age of the 93 patients ranged between 50 and 85 years, the average was 62.45 ± 8.93 SD. They had bilateral adnexectomy for ovarian cyst found after ultrasound exam. The histological profiles revealed 89 benign (95.7%) corresponding to 83 ovarian cysts and 6 tubal or para-ovarian cysts, 3 malignant (3.2%) and 1 borderline tumour (1.1%). These data are summarized in Table 1 and Figure 1. Among the malignant tumors were 1 ovarian cancer at early stage, 1 metastatic cancer of endometrial origin and 1 advanced ovarian cancer. Of the benign lesions, 6 did not belong to the ovary (para-ovarian benign cysts and hydrosalpinx). Every ultrasound image representing cyst was analyzed and IOTA simples' rules were applied. The IOTA score classified 74 images as

benign lesions (79.6%), 2 as malignant lesions (2.1%) and 17 unable to be classified (18.3%). All of ovarian tumors classified as benignant by IOTA score were really benignant after histological examination. Likewise, when the IOTA score was in favour of malignant neoplasia, the histological analysis confirmed ovarian cancer (bilateral high grade serous ovarian cancer stage pT2b, metastatic endometroid adenocarcinoma of endometrial origin). Anyway, 2 of these 17 lesions unable to be classified by IOTA score (11.8%) were high risk neoplasms (a borderline tumour and an early stage ovarian cancer, FIGO stage 1A serous-papillary histologic type). The ADNEX model algorithm was applied to IOTA score with unclassifiable cystic images. All of high risk lesions (cancers and borderline tumour) had an estimated malignancy probability greater than 10%, threshold established by anterior series (Figure 2) [26, 27]. Among the 15 benign cysts unable to be classified by IOTA score, 14 presented a low malignancy probability after ADNEX model scoring. Only one presented an estimated risk higher than 10%, corresponding to a solid lesion (pediculate fibroid). Once combined, the 2 methods yielded sensitivity and specificity rates of 100 and 98% respectively. Evaluation of malignancy risks by the 2 tests highlighted a negative predictive value of 100%: there was no case of false negative. However, a case of false positive was found.

Concerning the preoperative assessment, ultrasound exam was carried out for all of recruited patients. Pelvic imaging by MRI scan was performed for 32 patients with benign lesion (39%), 7 patients of unclassifiable group by IOTA score (41.2%) and none patient in the high-risk lesions in whom a tomographic scan was performed in all cases. Blood markers were determined in 66 patients (80.5%) of the benign lesions and one of the malignant lesions group (33%).

4. Discussion

A careful analysis of ovarian mass ultrasound image in post-menopausal patient constitutes a requisite step of preoperative workup. Our results showed that pelvic transvaginal ultrasound scan represents an excellent tool of triaging ovarian masses. Ultrasound's performance is good if the images are interpreted in a standardized and acceptable manner codified by the IOTA group with IOTA classification and score [13-17]. In case of lesion unable to be classifying by this score, the malignancy risk calculation is mandatory. It's recommended to perform the analysis of serum markers and to apply multimodal algorithm for malignant risk estimation. This diagnostic pattern can be proposed for the evaluation of this type of ovarian cyst insofar as we found two malignant and a borderline tumors. ADNEX model algorithm distinguishes well between benign and malignant tumors and offers fair to excellent discrimination between four types of ovarian malignancy. This non-binary (benign / malignant) algorithm was the first risk model that differentiates between benign and types of malignant ovarian tumors (borderline, stage I cancer, stage II-IV cancer, and secondary metastatic cancer). It has the potential to improve triage and management decisions and so reduce morbidity and mortality associated with adnexal pathology insofar as borderline tumors and stage I cancers can beneficiate of less aggressive management in non-menopausal wives, to preserve their fertility particularly [17, 24].

Our data allow us to evaluate the predictive performance of IOTA score and ADNEX model in our patents' series. Thus, the IOTA score showed high specificity because there weren't false negatives. Also, the positive predictive value and the specificity of IOTA score were high, in fact we didn't found any false positive. Every cyst classified as malignant by IOTA score was really malignant after histological exam. Nevertheless, many ovarian masses couldn't be classified by IOTA score. Among unclassified cysts, 3 were at high risk lesions (2

cancers and a borderline tumour). If they were considered as false negatives, the sensitivity of IOTA score falls to 25%. This appears no sufficient for a screening test whose performance require high sensitivity. Therefore, in case of ultrasound ovarian image unable to be classified by IOTA score, revaluation of risk by multimodal algorithm is needed. The calculation of the risk of malignancy makes it possible to determine correct medical management as surgical treatment, surgical treatment in oncological unit or medical follow-up. Indeed, this diagnostic path enables to avoid two medicals errors that could be committed. First, operating asymptomatic benign ovarian cysts unnecessarily increases the risk of surgical complications. Second, ignoring an early stage of ovarian cancer or a borderline tumour may darken the prognosis [8]. Correct diagnosis of malignancy risk leads to referral of patients with ovarian cancer to gynecological oncological centers for adequate diagnosis and management as surgery and systemic therapy. Similarly, benign lesions can be managed expectantly or by conservative surgical procedures. This distinction may improve patient care significantly. ADNEX model algorithm was chosen for that purpose [17]. According with literature, we used as cut-off a malignancy risk greater than 10% due to patient's age [24]. This algorithm showed a sensitivity of 100% in our patients' series. Every high-risk lesion had an estimated malignancy risk greater than 20%. The specificity of ADNEX model was also good (98.8%) insofar as only a false positive was detected among cysts unclassified by IOTA score. This was a solid lesion, whose histological exam found a pediculate fibroma. Thus, the ADNEX model's performance in our series was considered satisfactory. Concerning the negative predictive value, it appeared optimal for IOTA score, excluding unclassified images, and also for ADNEX model. After using successively these predictive scores independently, we aimed to evaluate the screening performance of the two tests' association. Sensitivity and negative predictive value were excellent. The analysis showed a case of false positive. We didn't found any false negative with the two methods, what may appear as auspicious for tests designated

to screening of ovarian malignancy. Thus, even if the evaluation of the expert ultrasonographer remains an effective modality to characterize ovarian masses, we would expect these models to aid in their correct management. Moreover, their preoperatively use, combined with the intraoperative macroscopic evaluation could help the surgical team to better discriminate malignant tumors and thus guide surgical decision [24]. A tumor size threshold of 7 cm is considered as one of the limitations of endovaginal ultrasound; a MRI can thus be discussed [22,24].

Ultrasound assessment of ovarian mass could be carried out even in an emergency context due to the accessibility of this examination. IOTA score and ADNEX model also remain applicable to this situation. Indeed, in our cases series, we found two ovarian cancers that underwent urgent surgery for suspicion of torsion of the adnexa. In those cases, surgical treatment wasn't complete. Ovarian masses' triage has to be carried out in a standardized manner in order to respect IOTA score's criteria. From a practical point of view, we have printed and displayed the photo representing the ultrasonic characteristics of the IOTA classification, available from the IOTA group's website (www.iotagroup.org), in our ultrasound rooms in order to facilitate and systematize its use. This can contribute to standardizing the subsequent management of the adnexal masses (Figure 3). Cyst identifications can be established by inexperienced sonographers, sometimes in an emergency setting. These rules can help these practitioners to correctly interpret images and classify them as presumed benign or not in order to adjust the delay of management by an expert sonographer [10].

Although it highlights serious avenues of reflection, this study has a weakness insofar as these findings are the result of a retrospective study with a relatively limited cohort of patients. Any suspicious or not easily diagnosed ovarian mass requires sonography by an expert to provide an accurate characterization [28]. This subjective but reliable assessment remains essential

and increases with experience. All cases were previously reviewed by an experienced sonographer before retaining any surgical indication. Moreover, retrospective analysis of the images was performed by a same gynecologist expert sonographer.

Conclusion

Ultrasound scan is appropriate to ovarian cancer screening for postmenopausal patients. Some models and rules have been developed and validated to assist ultrasound examiners with varying levels of experience in making accurate diagnosis. IOTA score allows identifying high-risk masses. In case of undetermined lesions, multimodal algorithm ADNEX can be required for malignancy risk calculation. Their combination as risks prediction models can improve the performance of pelvic ultrasound and discriminate between benign and malignant cysts in postmenopausal women, especially for undetermined lesions.

We have no conflict of Interest

5. References

1) Salat-Baroux J, Merviel P, Kuttenn F. Management of ovarian cysts. BMJ 1996; 313(7065): 1098
2) Siegel R, Ma J, Zou Z, Jemal A. Cancer statistics, 2014. CA Cancer J Clin 2014; 64: 9-29
3) Berrino F, De Angelis R, Sant M, Rosso S, Lasota MB, et al. Survival for eight major cancers and all cancers combined for European adults diagnosed in 1995-1999: results of the EUROCARE-4 study. Lancet Oncol 2007; 8: 773-83.
4) Howlader N, Noone AM, Krapcho M, Garshell J, Miller D, et al. SEER cancer statistics review, 1975-2011. National Cancer Institute (Bethesda, MD), Apr 2014. https://seer.cancer.gov/archive/csr/1975_2011/. Read 05/07/2017.
5) Buys SS, Partridge E, Black A, Johnson CC, Lamerato L, et al. Effect of screening on ovarian cancer mortality: the Prostate, Lung, Colorectal and Ovarian (PLCO) Cancer Screening Randomized Controlled Trial. JAMA 2011; 305: 2295-303.
6) Kobayashi H, Yamada Y, Sado T, Sakata M, Yoshida S, et al. A randomized study of screening for ovarian cancer: a multicenter study in Japan. Int J Gynecol Cancer 2008; 18: 414-20.
7) Khoury-Collado F, Bombard AT. Hereditary breast and ovarian cancer: what the primary care physician should know. Obstet Gynecol Surv 2004; 59: 537-42.

8) Vinatier D, Houfflin V, Collinet P. Tumor markers and ovarian cysts. J Gynecol Obstet Biol Reprod (Paris) 2001; 30: S34-40.

9) Timmerman D, Testa AC, Bourne T, Ameye L, Jurkovic D et al. Simple ultrasound-based rules for the diagnosis of ovarian cancer. Ultrasound Obstet Gynecol 2008; 31: 681–690.

10) Timmerman D, Ameye L, Fischerova D, Epstein E, Melis GB, et al. Simple ultrasound rules to distinguish between benign and malignant adnexal masses before surgery: prospective validation by IOTA group. BMJ 2010; 14: 341:c6839.

11) Testa A, Kaijser J, Wynants L, Fischerova D, Van Holsbeke C et al. Strategies to diagnose ovarian cancer: new evidence from phase 3 of the multicentre international IOTA study. Br J Cancer 2014; 111: 680-8

12) Alcázar JL, Pascual MA, Olartecoechea B, Graupera B, Aubá M et al. IOTA simples rules for discriminating between benign and malignant adnexal masses: prospective external validation. Ultrasound Obstet Gynecol 2013; 42: 467-71

13) Jacobs I, Oram D, Fairbanks J, Turner J, Frost C, et al. A risk of malignancy index incorporating CA 125, ultrasound and menopausal status for the accurate preoperative diagnosis of ovarian cancer. Br J Obstet Gynaecol 1990; 97: 922–9.

14) Geomini P, Kruitwagen R, Bremer GL, Cnossen J, Mol BW. The accuracy of risk scores in predicting ovarian malignancy: a systematic review. Obstet Gynecol 2009; 113: 384–94.

15) Clarke SE, Grimshaw R, Rittenberg P, Kieser K, Bentley J. Risk of malignancy index in the evaluation of patients with adnexal masses. J Obstet Gynaecol Can 2009; 31: 440-5

16) Timmerman D, Antonia C, Testa, Bourne T, Ferrazzi E et al ; Logistic regression model to distinguish between the benign and malignant adnexal mass before surgery:

A multicenter study by the International Ovarian Tumor Analysis Group. J Clin Oncol 2005; 23: 8794-801

17) Van Calster B, Van Hoorde K, Valentin L, Testa AC, Fischerova D, et al. Evaluating the risk of ovarian cancer before surgery using the ADNEX model to differentiate between benign, borderline, early and advanced stage invasive, and secondary metastatic tumours: prospective multicentre diagnostic study. BMJ 2014; 349: g5920

18) Yoruk P, Dundar O, Yildizhan B, Tutuncu L, Pekin T. Comparison of the risk of malignancy index and self-constructed logistic regression models in preoperative evaluation of adnexal masses. J Ultrasound Med 2008; 27: 1469-77

19) Meys EM, Jeelof LS, Achten NM, Slangen BF, Lambrechts S, et al. Estimating the risk of malignancy in adnexal masses: external validation of the ADNEX model and comparison with other frequently used ultrasound methods. Ultrasound Obstet Gynecol 2017; 49: 784-92.

20) Vergote I, De Brabanter J, Fyles A, Bertelsen K, Einhorn N et al. Prognostic importance of degree of differentiation and cyst rupture in stage I invasive epithelial ovarian carcinoma. Lancet 2001; 357: 176-82.

21) Timmerman D, Valentin L, Bourne TH, Collins WP, Verrelst H et al. Terms, definitions and measurements to describe the sonographic features of adnexal tumors: a consensus opinion from the International Ovarian Tumor Analysis (IOTA) Group. Ultrasound Obstet Gynecol 2000; 16: 500-5

22) Brun JL, fritel X, Aubard Y, Borghese B, Bourdel N et al. Management of presumed benign ovarian tumors: updated French guidelines. Eur J Obstet Gynecol Reprod Biol 2014; 183: 52-8.

23) Moore RG, Miller MC, Disilvestro P, Landrum LM, Gajewski W et al. Evaluation of the diagnostic accuracy of the risk of ovarian malignancy algorithm in women with a pelvic mass. Obstet Gynecol 2011; 118: 280-8.

24) Joyeux E, Miras T, Masquin I, Duglet PE, Astruc K et al. Before surgery predictability of malignant ovarian tumors based on ADNEX model and its use in clinical practice. Gynecol Obstet Fertil 2016; 44: 557-564.

25) Heintz AP, Odicino F, Maisonneuve P, Quinn MA, Benedet JL, et al. Carcinoma of the ovary. FIGO 26th Annual Report on the Results of Treatment in Gynecological Cancer. Int J Gyanecol Obstet 2006; 95: S161-92.

26) Menon U, Gentry-Maharaj A, Hallett R, Ryan A, Burnell M, et al. Sensitivity and specificity of multimodal and ultrasound screening for ovarian cancer, and stage distribution of detected cancers: results of the prevalence screen of the UK Collaborative Trial of Ovarian Cancer Screening (UKCTOCS). Lancet Oncol 2009; 10: 327-40.

27) Van Calster B, Van Hoorde K, Froyman W, Kaijser J, Wynants L et al. Practical guidance for applying the ADNEX model from the IOTA group to discriminate between different subtypes of adnexal tumors. Fact Views Vis Obgyn 2015; 7: 32-41.

28) Marret H, Cayrol M. Sonographic diagnosis of presumed benign ovarian tumors. J Gynecol Obstet Biol Reprod (Paris). 2013;42:730-43.

	Benign lesions	Malignant lesions	Borderline
Patients n=93 (percentage)	89 (95.7%)	3 (3.2%)	1 (1.1%)
Average age (years)	61,7	63,6	63
Average size of the lesion (cm)	3,2	18,6	12

Figures captions

Table 1: Patients and lesions' features

Figure 1: Patients selection flow chart including histological data

Figure 2: True-negative (A) and true-positive (B) lesions rates for the ADNEX model and the IOTA score

Figure 3: Decision tree summarizing our management of a cystic ultrasound image (graphical abstract)

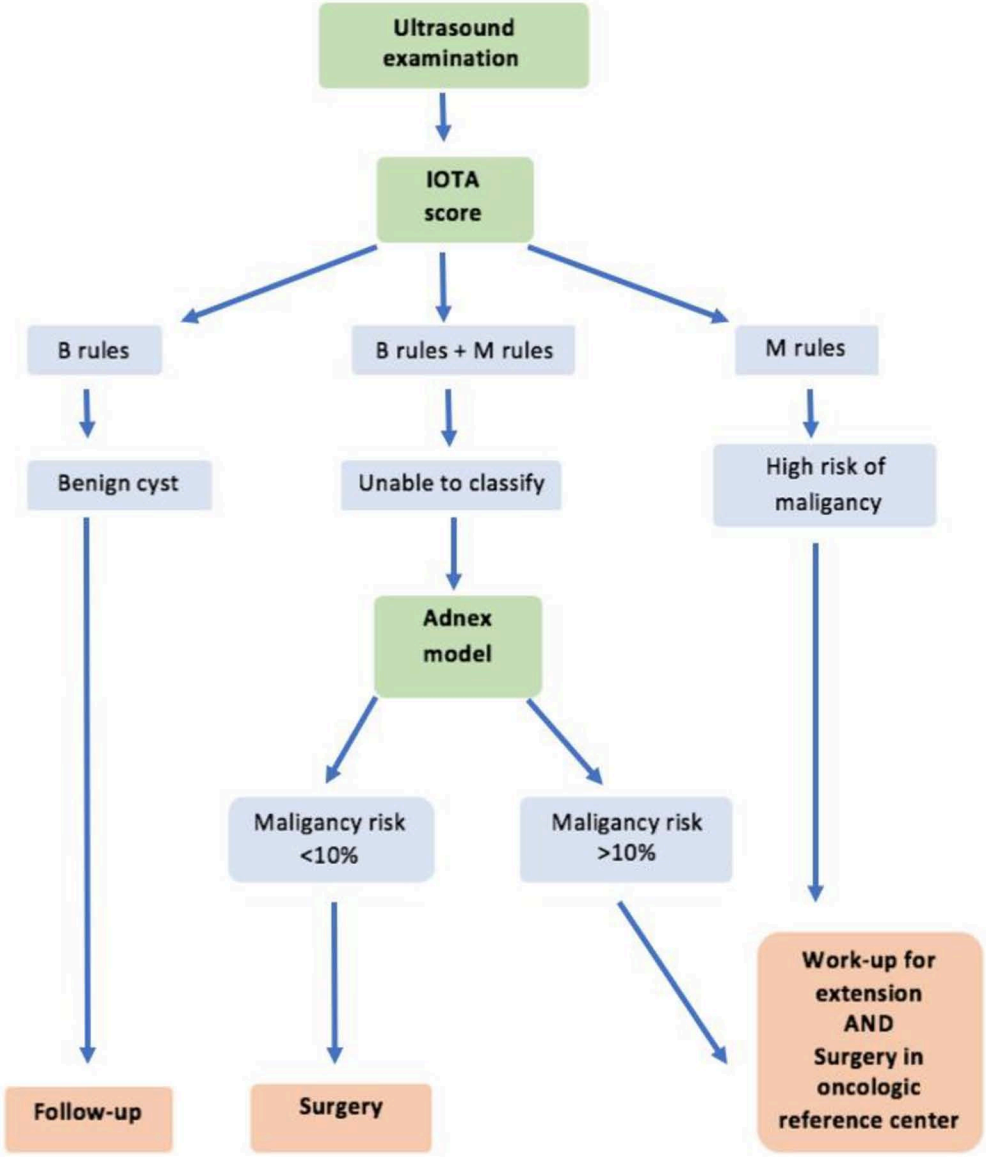
Ultrasound examination
IOTA score
B rules
B rules + M rules
M rules
Benign cyst
Unable to classify
High risk of maligancy
Adnex model
Maligancy risk <10%
Maligancy risk >10%
Work-up for extension AND Surgery in oncologic reference center
Follow-up
Surgery

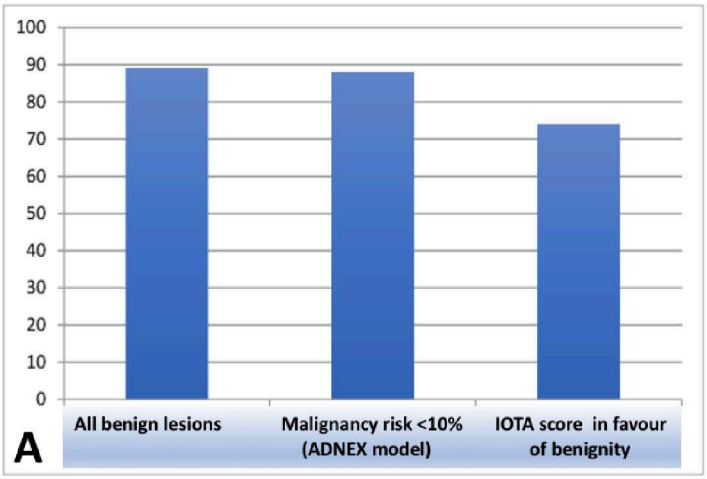
100
90
80
70
60
50
40
30
20
10
0
All benign lesions
Malignancy risk <10% (ADNEX model)
IOTA score in favour of benignity
A

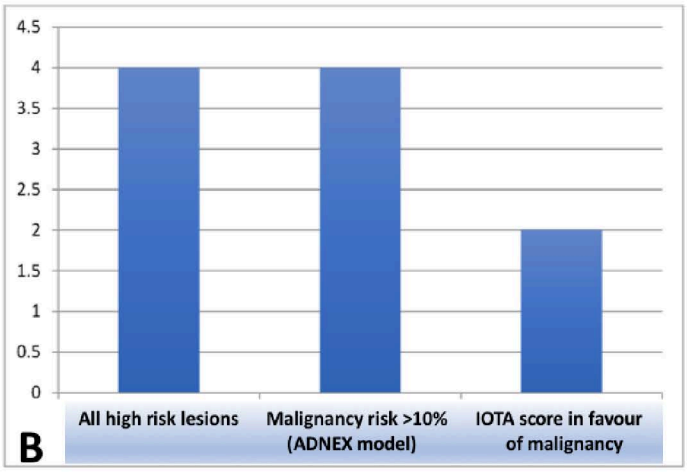
4.5
4
3.5
3
2.5
2
1.5
1
0.5
0
All high risk lesions
Malignancy risk >10% (ADNEX model)
IOTA score in favour of malignancy
B

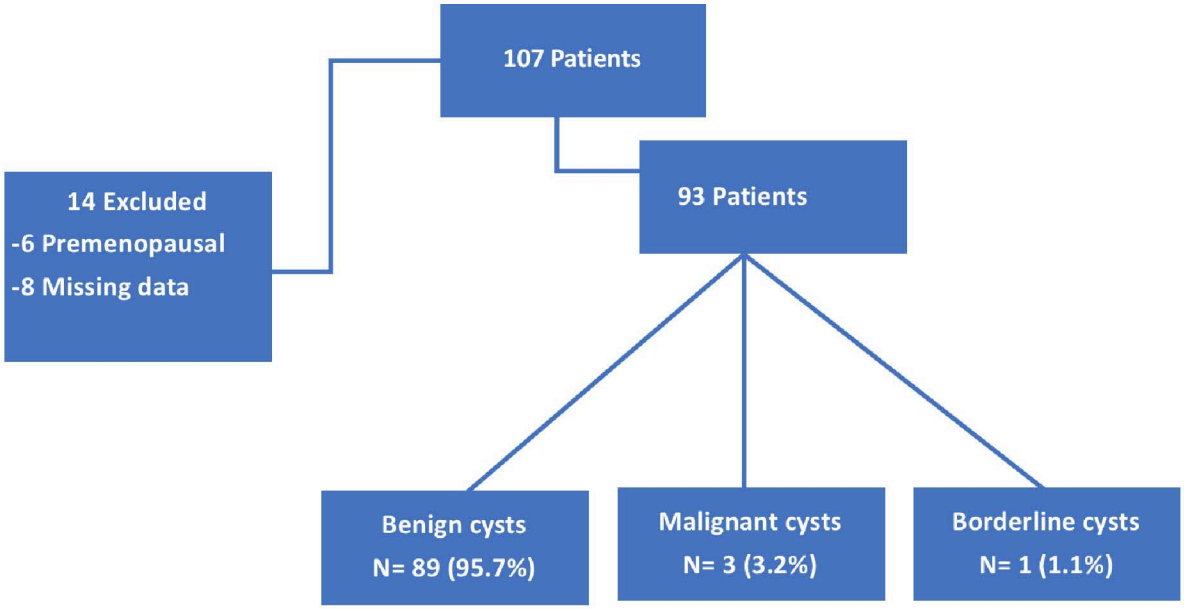
107 Patients
14 Excluded
-6 Premenopausal
-8 Missing data
93 Patients
Benign cysts
N= 89 (95.7%)
Malignant cysts
N= 3 (3.2%)
Borderline cysts
N= 1 (1.1%)