



**HAL**  
open science

## **ECMM/ISHAM recommendations for clinical management of COVID -19 associated mucormycosis in low- and middle-income countries**

Shivaprakash M Rudramurthy, Martin Hoenigl, Jacques F Meis, Oliver A Cornely, Valliappan Muthu, Jean Pierre Gangneux, John Perfect, Arunaloke Chakrabarti

### ► To cite this version:

Shivaprakash M Rudramurthy, Martin Hoenigl, Jacques F Meis, Oliver A Cornely, Valliappan Muthu, et al.. ECMM/ISHAM recommendations for clinical management of COVID -19 associated mucormycosis in low- and middle-income countries. *Mycoses*, 2021, 64 (9), pp.1028-1037. 10.1111/myc.13335 . hal-03282540

**HAL Id: hal-03282540**

**<https://hal.science/hal-03282540>**

Submitted on 8 Sep 2021

**HAL** is a multi-disciplinary open access archive for the deposit and dissemination of scientific research documents, whether they are published or not. The documents may come from teaching and research institutions in France or abroad, or from public or private research centers.

L'archive ouverte pluridisciplinaire **HAL**, est destinée au dépôt et à la diffusion de documents scientifiques de niveau recherche, publiés ou non, émanant des établissements d'enseignement et de recherche français ou étrangers, des laboratoires publics ou privés.

PROFESSOR SHIVAPRAKASH M RUDRAMURTHY (Orcid ID : 0000-0002-9097-9253)

DR JEAN PIERRE GANGNEUX (Orcid ID : 0000-0002-4974-5607)

DR ARUNALOKE CHAKRABARTI (Orcid ID : 0000-0003-1555-3807)

Article type : Original Article

## **ECMM/ISHAM recommendations for clinical management of COVID -19 associated mucormycosis in low- and middle-income countries**

Shivaprakash M Rudramurthy<sup>1</sup>, Martin Hoenigl<sup>2,3</sup>, Jacques F. Meis<sup>4</sup>, Oliver A. Cornely<sup>5,6,7</sup>, Valliappan Muthu<sup>1</sup>, Jean Pierre Gangneux<sup>9</sup>, John Perfect<sup>10</sup>, Arunaloke Chakrabarti<sup>1</sup>, on behalf of ECMM and ISHAM

### **Affiliations**

<sup>1</sup> Department of Medical Microbiology, Postgraduate Institute of Medical Education and Research, Chandigarh, Chandigarh 160012, India

<sup>2</sup> Division of Infectious Diseases, Department of Internal Medicine, Medical University of Graz, Graz, Austria

<sup>3</sup> Division of Infectious Diseases and Global Public Health, University of California San Diego, San Diego, USA

<sup>4</sup> Department of Medical Microbiology and Infectious Diseases, Center of Expertise in Mycology Radboud University Medical Center/ Canisius Wilhelmina Hospital, Nijmegen, the Netherlands

<sup>5</sup> University of Cologne, Faculty of Medicine and University Hospital Cologne, Department I of Internal Medicine, Excellence Center for Medical Mycology (ECMM), Cologne, Germany

<sup>6</sup> University of Cologne, Faculty of Medicine, Chair Translational Research, Cologne Excellence Cluster on Cellular Stress Responses in Aging-Associated Diseases (CECAD), Cologne, Germany

This article has been accepted for publication and undergone full peer review but has not been through the copyediting, typesetting, pagination and proofreading process, which may lead to differences between this version and the [Version of Record](#). Please cite this article as [doi: 10.1111/MYC.13335](https://doi.org/10.1111/MYC.13335)

<sup>7</sup> German Centre for Infection Research (DZIF), Partner Site Bonn-Cologne, Cologne, Germany

<sup>8</sup> Department of Pulmonary Medicine, Postgraduate Institute of Medical Education and Research, Chandigarh, Chandigarh 160012, India

<sup>9</sup> Université de Rennes, CHU Rennes, Inserm, EHESP, Irset (Institut de recherche en santé, environnement et travail) – UMR\_S 1085, F-35000 Rennes, France.

<sup>10</sup> Department of Medicine, Division of Infectious Diseases, Duke University Medical Center, Durham NC, USA

**Running Title**

COVID-associated mucormycosis

**Keywords**

COVID-19, *Mucorales*, diabetes, corticosteroids, infection, SARS-CoV2, mucormycosis

**Corresponding Author**

Arunaloke Chakrabarti, M.D.

Department of Medical Microbiology

Postgraduate Institute of Medical Education and Research, Chandigarh

Chandigarh 160012

India

Phone: +91 9914208244

E-mail: arunaloke@hotmail.com

## Abstract

Reports are increasing on the emergence of COVID-19 associated mucormycosis (CAM) globally, driven particularly by low- and middle-income countries. The recent unprecedented surge of CAM in India has drawn worldwide attention. More than 28,252 mucormycosis cases are counted and India is the first country where mucormycosis has been declared a notifiable disease (1). However, misconception of management, diagnosing and treating this infection continue to occur. Thus, European Confederation of Medical Mycology (ECMM) and the International Society for Human and Animal Mycology (ISHAM) felt the need to address clinical management of CAM in low- and middle-income countries. This article provides a comprehensive document to help clinicians in managing this infection. Uncontrolled diabetes mellitus and inappropriate (high dose or not indicated) cortico-steroid use are the major predisposing factors for this surge. High counts of *Mucorales* spores in both the indoor and outdoor environments, and the immunosuppressive impact of COVID-19 patients as well as immunotherapy are possible additional factors. Furthermore, a hyperglycaemic state leads to hyper-ferritinaemia and increased expression of glucose regulated protein (GRP- 78) in endothelial cells that may help the entry of *Mucorales* into tissues. Rhino-orbito-cerebral (ROC) mucormycosis is the most common presentation followed by pulmonary mucormycosis. Recommendations are focused on the early suspicion of the disease and confirmation of diagnosis. Regarding management, glycaemic control, elimination of corticosteroid therapy, extensive surgical debridement and antifungal therapy are the standards for proper care. Due to limited availability of amphotericin B formulations during the present epidemic, alternative antifungal therapies are also discussed.



## Introduction

The current pandemic of Coronavirus disease (COVID-19) caused by novel Coronavirus SARS - CoV-2 has already affected more than 174 million and has killed 3.8 million people across the world. Mortality is causally related to the severe pneumonia caused by SARS-CoV-2 along with an aberrant host immune response in the form of a cytokine storm. Secondary infections due to bacteria and fungi increase the mortality rate (2,3). Among fungal infections, COVID-19 associated pulmonary aspergillosis (CAPA) carries a high mortality, with an all-cause mortality ranging between 33%-80%, as the diagnosis of CAPA is difficult (4–6). Due to overlapping clinical features of CAPA and COVID-19 associated acute respiratory distress syndrome (ARDS), the European Confederation of Medical Mycology (ECMM) and International Society for Human and Animal Mycology (ISHAM) jointly defined diagnostic criteria and management protocol of patients with CAPA.(4) Mucormycosis did not draw similar attention, as the disease was considered rare. Recent reviews on worldwide cases highlighted the importance of COVID-19 associated mucormycosis (CAM) globally (7–10). Particularly the recent unprecedented surge of CAM in India has drawn worldwide attention (11,12). During the last year, a 2.1 time increase of mucormycosis prevalence was reported due to COVID-19 in a multicentre study in India (11). However, this year those numbers have been exploding: Already more than 28,252 mucormycosis cases have been reported and mucormycosis has been declared a notifiable disease in India (1). Although the ECMM and the Mycoses Study Group (MSG) together developed a global guideline for diagnosis and management of mucormycosis (13), we felt the need to address the specific issues related to CAM such as any misconceptions on the management, diagnosing and managing this infection that more frequently occur in low and middle income countries (LMIC). Experts from ISHAM and ECMM prepared recommendations to help clinicians manage this infection.

## Aetiology and risk factors

Mucormycosis is caused by few genera of fungi in the order *Mucorales* of the phylum *Mucormycota*. The phylum *Mucormycota* comprises 55 genera with 261 species of which 38 are known to be human pathogens (14). Common species causing mucormycosis include *Rhizopus* spp., *Rhizomucor* spp., *Mucor* spp., *Lichtheimia* spp., *Apophysomyces* spp., *Cunninghamella* spp., and *Saksenaea* spp. Present data suggest that *Rhizopus arrhizus* is the predominant agent causing CAM in India (11). The distribution of different species varies amongst different geographical

regions. For instance, *Rhizopus arrhizus* is the most common species in India (15,16) and France (17) but *Cunninghamella* spp. is most common in Spain (18).

*Mucorales* are thermo-tolerant fungi with a ubiquitous distribution. They are found on organic substrates such as decaying fruit and vegetable matter, crop debris, bread, compost piles, animal excreta and soil within indoor and outdoor environments (19). An ecological study conducted in India revealed presence of many species of *Mucorales* in soil (20). *Mucorales* are also present in indoor environments such as air conditioning filters (21,22). A recent study from North India reported large numbers of *Mucorales* spores in both hospitals and outdoor air (21). The mean spore count of *Mucormycetes* in outdoor samples ranged between 0.73 to 8.60 cfu/m<sup>3</sup> across different seasons. Within the hospital, the mean spore count was slightly higher in an airconditioned area (0.88 - 1.72 cfu/m<sup>3</sup>) compared to a non-airconditioned area (0.68 - 1.12 cfu/m<sup>3</sup>) (21). *R. arrhizus* was the predominant *Mucorales* isolated in both indoor and outdoor air (21).

Rhino-orbito-cerebral mucormycosis (ROCM) and pulmonary mucormycosis are generally observed in patients with uncontrolled diabetes or having immunosuppressive conditions such as patients receiving corticosteroid treatment, cancer chemotherapy or immunotherapy, haematological stem cell transplants, those with prolonged neutropenia or solid organ transplants (13,15). In contrast cutaneous or subcutaneous mucormycosis is generally observed after trauma (15).

### **Pathogenesis of CAM**

The sporangiospores of *Mucorales* vary in size depending on species (range 3-11 µm). These spores are released from the sporangium and dispersed into the air, where a vulnerable host population may acquire an infection. Inhalation is the major route of acquiring mucormycosis. The relatively larger spores of *R. arrhizus* get trapped in the nasal epithelium and sinuses and thus may lead to ROCM, whereas the relatively smaller spores of *Cunninghamella* spp. can reach the lower respiratory tract leading to pulmonary mucormycosis (15). However, available evidence suggests that any pathogenic *Mucorales* species can produce any type of clinical presentation (23).

*Uncontrolled diabetes in CAM:* The major underlying disease noted in mucormycosis cases in LMICs such as India, Iran or Mexico is uncontrolled diabetes with or without ketoacidosis (14, 21, 22). Among COVID-19 patients, uncontrolled diabetes had been reported at 7-21%. However, the

prevalence in India is above 30%, with 2% of patients developing diabetic ketoacidosis. Acute or stress-induced hyperglycaemia has been noted in 50% of hospitalised COVID-19 patients (24). SARS-CoV-2 itself can induce acute diabetes and diabetic ketoacidosis by damaging pancreatic islets cells, which have a high expression of angiotensin converting enzyme-2 receptors, as has been noted with SARS-CoV-1, and indirectly by damaging small blood vessels supplying pancreatic beta cells (28,29). Increased resistance to insulin due to the profound inflammatory reaction, may also play some role in the induction of hyperglycaemia (9,30). In addition, a few cases of euglycemic diabetic ketoacidosis have been reported in COVID-19 cases, especially those receiving sodium-glucose co-transporter-2 inhibitors (SGLT2) (26,31).

Type 2 diabetes mellitus itself is an immunocompromised state which leads to dysregulated, dysfunctional innate and adaptive immune cells making the host susceptible to infections by *Mucorales* (32). Due to increased glycosylation, IL-10 production by lymphocytes and macrophages is significantly reduced. Diabetes mellitus also reduces polymorphonuclear leukocyte mobilization and chemotaxis (32). Hyperglycaemia and acidosis can induce phagocytic cell dysfunction leading to increased risk of *Mucorales* infections.

*Role of corticosteroids in CAM:* In a multicentre study from India, inappropriate corticosteroid use was noted in 63.3% patients (11). The situation was aggravated further during the second wave of COVID-19, when steroids were used indiscriminately and inappropriately to overcome the challenge of the oxygen acquisition crisis and resulting oxygen desaturation in patients. The over-the-counter availability and practice of self-medication with corticosteroids complicates the situation even further. The use of corticosteroids in the treatment of COVID-19 may act as a double-edged sword. Firstly, corticosteroids can increase blood glucose levels by acting as a substrate for oxidative stress metabolism with lipolysis, proteolysis, and hepatic glucose production. They also increase insulin resistance in up to 60%-80% of patients depending on the dose and type used (33). Secondly, they affect virtually all immune cells. Some major immune suppressive actions of corticosteroids are: i) antagonism of macrophage maturation and differentiation, ii) decrease of interleukin-1, interleukin-6, tumour necrosis factor, proinflammatory prostaglandins and leukotrienes production by macrophages, iii) suppression of microbicidal activity of activated macrophages (34). They also suppress neutrophil adhesion to endothelial cells and impair lysosomal enzyme release, respiratory burst, and chemotaxis to the site of infection (34). Increased risk of infection following glucocorticoid therapy is well

established, but the dose and the duration of steroid therapy required to increase the risk of different infections is not as well defined (35).

*Iron and hyperferritinaemia:* Iron overload and deferoxamine therapy are well known risk factors for mucormycosis (36). The free iron captured by siderophores of *Rhizopus* species helps in its growth (36). Severe COVID-19 is a hyperferritinaemic state due to hyperinflammation (37). In severe COVID-19 patients, ferritin level rises 1.5 to 5 times higher than in non-severe cases (average ferritin concentration of >800 µg/L) (37). High IL-6 concentrations in COVID-19 patients have been correlated to disease severity (38). IL-6 directly stimulates ferritin production and increases the synthesis of hepcidin which in turn sequesters iron in enterocytes and macrophages thus preventing them to efflux from these cells leading to increased intracellular iron load (39). This excess intracellular iron generates reactive oxygen species (ROS) causing damage to the tissue and free iron is released in the circulation and available to *Mucorales* (9,10,38)

*Endothelial damage:* Comparison of autopsy lung specimens obtained from expired patients due to COVID-19 and those with acute respiratory distress syndrome (ARDS) secondary to influenza A (H1N1) infection, has revealed severe vascular endothelial injury along with the presence of intracellular virus and disrupted cell membranes in COVID-19 deceased patients. Pulmonary vessels show widespread thrombosis along with significantly higher (9 times, P<0.001) alveolar capillary microthrombi in COVID-19 patients compared to patients with influenza (40).

Thrombosis can also occur in small veins supplying the pancreas, thereby damaging it and causing insulin deficiency leading to diabetes mellitus (41). As endothelial adhesion and penetration is an early step in establishing mucormycosis (36), endothelial damage observed in severe COVID-19 disease may play an important pathogenic role (9).

*Overexpression of GRP78:* Hyperglycaemia is a stress condition that induces the overexpression of the glucose regulated protein (GRP78) which is present in the lumen of the endoplasmic reticulum and expressed in mammalian cells (42). The CotH protein kinase belonging to the spore coating protein family in *Rhizopus* acts as the ligand for GRP78, which helps the fungus to adhere and invade endothelial and nasal epithelial cells (43). Sabrili et al. demonstrated significantly higher serum GRP78 levels in COVID 19 patients compared to a COVID 19 negative control group. These findings suggest amplified pathogenic role of GRP78 in CAM (44).

Therefore, the pathogenesis of CAM is a complex issue, in which environment, vulnerable patients, corticosteroid use, and COVID-19 play synergistic roles in the disease pathogenesis (Fig. 1).

### **When and how to clinically suspect CAM**

During the present epidemic nearly 90% of cases presented as ROCM and less than 10% as pulmonary or disseminated disease (11). Cutaneous mucormycosis is rarely reported in SARS-CoV-2 infected patients (10,11). Early diagnosis of CAM cases helps in prompt treatment which, in turn, reduces the mortality or morbidity of this infection. CAM can occur while the patient is actively suffering from the disease, during the in-hospital recovery stage or post-discharge after recovering from SARS-CoV-2 infection (10,11). Some important points to be considered while clinically diagnosing these conditions are described below. One should suspect CAM in any SARS-CoV-2 infected (present or past) uncontrolled diabetic patient who received corticosteroid therapy and develop the following features.

*Rhino-orbito-cerebral mucormycosis (ROCM):* Early warning signs of ROCM include facial pain, nasal blockade or congestion, bloody/brown/black discharge with or without local tenderness or pain. This can be associated with fever, nausea, and headache. Nasal ulcers or crusts turning black later in the course of disease are often noted. Furthermore, patients may develop facial numbness or oedema during involvement of the maxillary, frontal, or ethmoidal paranasal sinuses. Palatal involvement may be noted in the form of an ulcer over the upper palate leading to a dark necrotic area (Fig 2A). It may also present as toothache and/or loosening of maxillary teeth and restriction of jaw movement which was not noted during pre-COVID-19 times (11). With invasion into the orbit the patient may initially have blurring of vision or diplopia, orbital pain, paraesthesia, or proptosis (Fig 2B). The orbital apex syndrome without pain has also been well-described. An eschar may be seen in the nasal septum, palate, eyelid, face, or orbital areas. Cranial nerve palsies are also common. With invasion of the brain the patient may present with features of cerebral oedema such as coma, and vascular invasion may lead to cerebral infarcts. Another common presentation includes sinus cavernous thrombosis following loss of vision.

*Pulmonary mucormycosis:* Solitary pulmonary CAM is difficult to diagnose and a radiological imaging is needed as several symptoms may overlap with pulmonary features of COVID-19 and of invasive aspergillosis (7). Fever, cough, haemoptysis, chest pain and pleural effusions are generally present. However, features such as haemoptysis, and tissue infarction are particularly characteristic of pulmonary mucormycosis (7,11). Pulmonary mucormycosis is usually the form observed in neutropenic patients.

### **Diagnosis of CAM**

Complete details on the diagnosis of mucormycosis has been given by Cornely et al. in the ECMM/MSG worldwide guidance (13). Basic investigations such as regular determination of blood glucose levels, ferritin levels, arterial blood gas measurements to rule out acidosis, serum electrolyte imbalance, along with screening for serum or urine ketone bodies are recommended for severe COVID-19 patients.

For diagnosis of CAM, COVID-19 should be confirmed by a single RT PCR test detecting the RNA of SARS-CoV-2, or SARS-CoV-2 antigen testing along with clinical, radiological, histopathological, or microbiological evidence suggestive of mucormycosis.

*Imaging:* In case of suspicion of ROCM, patients should undergo imaging studies such as computed tomography (CT) or magnetic resonance imaging (MRI) of brain and paranasal sinuses. MRI has an advantage over CT as it can determine the extent of fungal invasion whereas CT is better in identifying the bony erosion, which is noted in advanced stages of infection (13).

Radiological features of ROCM are mucosal thickening and opacification of the sinuses, oedema, inflammation, or infarction of the brain (Fig 2C, 2D).

Radiological features of pulmonary mucormycosis are non-specific and difficult to interpret as many features overlap with other fungal pneumonias such as pulmonary aspergillosis. The reverse halo sign is commonly associated with pulmonary mucormycosis (10). Other features include signs of pleural effusions and multiple nodules. Lung CT may confuse with COVID-19 related shadows so in such cases mucormycosis should be suspected when there is a thick-walled lung cavity (need to differentiate from COVID-19 associated pulmonary aspergillosis), reverse halo sign, multiple nodules, and pleural effusions (13) (Fig 3).

*Mycological diagnosis:* A definitive diagnosis can be made by microbiological and/or histopathological examination of tissues obtained from different lesions. Nasal samples from ROCM, broncho alveolar lavage (BAL) samples, mini-BAL, non-bronchoscopic lavage, transbronchial biopsy from pulmonary mucormycosis may provide an early clue of infection. The samples are first examined with KOH or KOH calcofluor-white, which demonstrate characteristic broad aseptate or pauci-septate hyphae (measuring 6-16 or even up to 25  $\mu\text{m}$ ) with folding of the hyphae giving a ribbon-like appearance (FIG-4A). Right-angle branching can be often noted especially on histopathological examination. Demonstration of this kind of hyphae and isolation of *Mucorales* from endoscopically collected debrided tissue/biopsy or a CT guided biopsy from a lung lesion confirms the diagnosis of mucormycosis. For successful isolation of *Mucorales*, tissue or biopsy samples should not be homogenized or grinded but instead it should be cut into small bits using scissors before inoculating culture media. Homogenization damages the fragile cell wall of *Mucorales* making the fungi non-viable resulting in no growth on the media. In culture, *Mucorales* can easily be identified as they typically produce cottony growth (Fig-4B), and with histopathology stains, angioinvasion and occlusion of the vessels with thrombi, necrosis, and haemorrhagic infarction can be noted. PCR based molecular techniques have been shown to have high sensitivity especially from fresh tissue sections (45–47). A real time PCR-based kit is commercially available for the detection of *Mucorales* DNA in various clinical specimens (48,49). Identification of *Mucorales* to species level is based on microscopic features (Fig 4C), PCR followed by sequencing and Matrix-Assisted Laser Desorption/Ionization-Time of Flight (MALDI-TOF) (13). Though no biomarker is available for the diagnosis of mucormycosis, repeated negative galactomannan antigen, 1,3- $\beta$ -D-glucan, and *Aspergillus* specific PCR results in a patient with strong suspicion of invasive mould infections of the lungs may suggest pulmonary mucormycosis (13).

### **Treatment approaches for CAM**

Standard approaches for the management of CAM are similar to the management of mucormycosis in non-COVID-19 patients, which are outlined in the ECMM-MSG global guideline (13).

For instance, early diagnosis of mucormycosis based on clinical, microbiological, histopathological, or radiological features is key for successful management. Controlling or eliminating the underlying predisposing factors such as diabetes, ketoacidosis, corticosteroids

intake, immunomodulators, and any immunosuppressant agents are crucial and help in preventing worsening of the disease. Invasive mucormycosis is a medical emergency condition and frontline antifungal therapy with amphotericin B (optimally lipid based formulations) should be initiated at the earliest, as a delay of  $\geq 6$  days in certain patients is associated with 2-fold increase in mortality rate at 12 weeks (50). Management of mucormycosis is a team effort depending on presentation and extent of involvement. The team generally constitutes an infectious diseases specialist, microbiologist, ENT surgeon, general surgeon, maxillofacial surgeon, intensivist, ophthalmologist, neurologist, histopathologist, radiologist, and pharmacologist (51).

*Surgical management:* Early and aggressive surgical resection and debridement of affected tissues is necessary for local control of mucormycosis (13).

In ROCM infection complete debridement of the external infected tissues including bones as well as internal tissues by endoscopic debridement or orbital exenteration results in higher survival rates (13). In cases of recurrence, repeated resection and debridement is necessary. In pulmonary mucormycosis, resection of the affected lung (if localized or single lobe is involved) may be beneficial to the patient by preventing him/her from undergoing emergency surgery for controlling bleeding in a later course of disease further increasing the chance of survival.

*Antifungal therapy:* Amphotericin B (if available as lipid-based formulations) is the drug of choice for first line therapy of mucormycosis. Among azoles, posaconazole and isavuconazole are effective, whereas itraconazole has shown *in-vitro* activity against *Mucorales*. Of all the different injectable amphotericin B formulations (liposomal amphotericin B, amphotericin B deoxycholate, amphotericin B lipid complex, amphotericin B colloidal dispersion) available, liposomal amphotericin B is strongly recommended at a dose of 5mg/kg per day in 200ml of 5% dextrose over 2-3 h for 3-6 weeks.

The current epidemic of mucormycosis in India has led to limited availability or even non-availability (in certain regions) of amphotericin B, posaconazole or isavuconazole, making the situation imperative to use alternative antifungals. In the current Indian scenario where, antifungal drugs are not easily available, we agree with the recommendation of Fungal Infection Study Forum at Fig 5. However, we recommend to follow the global guideline on mucormycosis after the availability of antifungal drugs (13). Itraconazole is generally not recommended for the management of mucormycosis. In fact, there are only few case reports available using itraconazole



either alone or in combination with amphotericin B for mucormycosis (52–54). However, *in vitro* antifungal susceptibility testing has consistently shown itraconazole is active against *Mucorales* (55,56) but trial has not been done to evaluate its effect *in vivo*. In a recent multicentric study from India, it has been shown that the minimum inhibitory concentration values of itraconazole against all species of *Mucorales* are less than the epidemiological cut-off value (2 µg/ml) defined for *R. arrhizus* by Espinel Ingroff et al. (55,56). Hence when amphotericin B, isavuconazole and posaconazole are not available, itraconazole therapy, 200 mg thrice a day for 3-6 weeks may be considered. Intravenous therapy followed by itraconazole suspension are the preferred formulations. If only itraconazole capsules are available, they should be taken with acidic beverages such as cola. Concomitant use of proton-pump inhibitors decreases the absorption of this drug. Therapeutic drug monitoring should be done after 5 days of treatment with itraconazole.

Although a few reports on the use of iron chelators, especially deferasirox have shown improvement along with antifungal therapy, the evidence is not robust. Deferasirox may be considered in those patients who have diabetes as a risk factor but should probably be avoided in patients with a haematological malignancy (13).

### **Prevention and misconceptions**

Steps to prevent or reduce the occurrence of covid associated mucormycosis and misconception on the terminology and acquisition of infection is depicted in Fig 6.

### **Conclusion**

An urgent attention is essential to curb the epidemic of CAM in low- and middle-income countries, especially in India. Recent multi-centre study in India has confirmed that proper glycaemic control and appropriate steroid therapy behaviour are essential while managing COVID-19 patients. Early diagnosis is important for better outcome of CAM patients. Clinicians while discharging from COVID wards, should advice the diabetic patients on the early symptoms and signs of CAM. Mucormycosis management requires comprehensive facility of accurate diagnosis, competent surgical and medical team. Administration and pharma companies should work together to overcome the deficit of antifungal drugs at the earliest period of time. During the antifungal drug deficit period clinicians may manage the patients according to the guideline

suggested here. The epidemic has taught us those fungal diseases should not be neglected; training on managing fungal infections among laboratory personnel and clinicians are essential in each country especially in countries having high rate of fungal infection. Research is essential in fungal diseases especially those that disproportionately affect the large population of low- and middle-income countries.

### **Acknowledgments**

We acknowledge Dr Atul Patel, Sterling Hospital, Ahmedabad, India for providing the clinical and radiological images. We also thank Dr Shreya Singh, Department of Medical Microbiology, Postgraduate Institute of Medical Education and Research, Chandigarh for preparing the illustration (Fig 1 and 6).

### **Conflict of interest:**

MH received research funding from Pfizer, Astellas, Gilead, Scynexis, MSD and NIH. OAC reports grants and personal fees from Actelion, Amplyx, Astellas, Basilea, Cidara, Da Volterra, F2G, Gilead, MedPace, Merck/MSD, Pfizer, Scynexis; grants from DFG (German Research Foundation), German Federal Ministry of Research and Education, Immunic, Janssen, Medicines Company, Melinta Therapeutics; personal fees from Allecra Therapeutics, Al-Jazeera Pharmaceuticals, Biocon, Biosys, CoRe Consulting, Entasis, Grupo Biotoscana, IQVIA, Matinas, Menarini, Molecular Partners, MSG-ERC, Mylan, Nabriva, Noxxon, Octapharma, Paratek, PSI, Roche Diagnostics, Seres, Shionogi; others from Wiley (Blackwell); outside the submitted work. JPG received research fundings from Gilead and Pfizer. Other authors expressed no conflict of interest in preparation of the manuscript

**Data availability:** No new data is generated

**Authors' contributions:** AC, MH, OAC, JFM initiated the discussion for the recommendation, MH and JPG provided the recommendation on behalf of European Confederation of Medical Mycology, AC, JFM, OAC, JP provided the recommendation on behalf of International Society for Human and Animal Mycology, SMR and VM wrote the draft, all authors reviewed the manuscript.

### **Legends of Figures**

**Fig 1:** Schematic representation of pathogenesis of COVID-19 associated mucormycosis. This illustration was prepared using BioRender software.

**Fig 2:** Left facial and orbital swelling with chemosis in a case of rhino-orbital mucormycosis (A), and a large necrotic ulcer on the left half of palate in a patient with left maxillary mucormycosis (B). Coronal view of magnetic resonance imaging of paranasal sinuses showing bilateral maxillary and ethmoidal sinusitis (C), more involvement on right side, contrast study showed post contrast enhancement (D).

**Fig 3:** Computed Tomography (CT) thorax with CT pulmonary angiography showing reverse halo in left upper lobe (A), CT pulmonary angiography showed vessel occlusion sign (B & C).

**Fig 4:** Broad aseptate hyphae on potassium hydroxide wet mount (A), classical cottony appearance of *Rhizopus arrhizus* colony (B) Microscopic picture of *Rhizopus arrhizus* (C).

**Fig 5:** Treatment algorithm for CAM prepared by the Fungal Infections Study Forum (modified) (51) [CVC- central venous catheter; PICC - peripherally inserted central catheter; TDM - therapeutic drug monitoring]

**Fig 6:** Figure depicting prevention and misconception regarding COVID-19 associated mucormycosis.

## References

1. Statement from Health Minister, Government of India to press. <https://www.tribuneindia.com/news/nation/28-252-black-fungus-cases-in-india-265262> (last accessed, 8 May 2021)
2. Feldman C, Anderson R. The role of co-infections and secondary infections in patients with COVID-19. *Pneumonia*. 2021;13(1):5. doi: 10.1186/s41479-021-00083-w.
3. Al-Hatmi AMS, Mohsin J, Al-Huraizi A, Khamis F. COVID-19 associated invasive candidiasis. *J Infect* 2021;82(2):e45–46. doi.org/10.1016/j.jinf.2020.08.005
4. Koehler P, Bassetti M, Chakrabarti A, et al. Defining and managing COVID-19-associated pulmonary aspergillosis: the 2020 ECMM/ISHAM consensus criteria for research and clinical guidance. *Lancet Infect Dis*. 2021;21(6):e149-e162. doi: 10.1016/S1473-3099(20)30847-1.
5. Blaize M, Mayaux J, Nabet C, et al. Fatal Invasive Aspergillosis and Coronavirus Disease in an Immunocompetent Patient. *Emerg Infect Dis*. 2020;26(7):1636–1637.
6. Salmanton-García J, Sprute R, Stemler J., et al. COVID-19–Associated Pulmonary Aspergillosis, March–August 2020. *Emerg Infect Dis*. 2021;27(4):1077-1086.
7. Garg D, Muthu V, Sehgal IS, et al. Coronavirus Disease (Covid-19) Associated Mucormycosis (CAM): Case Report and Systematic Review of Literature. *Mycopathologia*. 2021;186(2):289–298. doi.org/10.1007/s11046-021-00528-2
8. Singh AK, Singh R, Joshi SR, Misra A. Mucormycosis in COVID-19: A systematic review of cases reported worldwide and in India. *Diabetes Metab Syndr Clin Res Rev*. 2021: doi.org/10.1016/j.dsx.2021.05.019
9. John TM, Jacob CN, Kontoyiannis DP. When uncontrolled diabetes mellitus and severe covid-19 converge: The perfect storm for mucormycosis. *J Fungi*. 2021;7(4):298 doi: 10.3390/jof7040298
10. Hoenigl M, Seidel D, Carvalho A, et al. The emergence of COVID-19 associated mucormycosis: Analysis of cases from 18 countries. *BioRxiv*. 2021; dx.doi.org/10.2139/ssrn.3844587
11. Patel A, Agarwal R, Rudramurthy SM, et al. Multicenter Epidemiologic Study of Coronavirus Disease–Associated Mucormycosis, India . *Emerg Infect Dis*. 2021;27(9). doi.org/10.3201/eid2709.210934

12. Mishra N, Mutya VSS, Thomas A, et al. A case series of invasive mucormycosis in patients with COVID-19 infection. *Int J Otorhinolaryngol Head Neck Surg.* 2021;7(5):867. dx.doi.org/10.18203/issn.2454-5929.ijohns20211583
13. Cornely OA, Alastruey-Izquierdo A, Arenz D, et al. Global guideline for the diagnosis and management of mucormycosis: an initiative of the European Confederation of Medical Mycology in cooperation with the Mycoses Study Group Education and Research Consortium. *Lancet Infect Dis.* 2019;19(12):e405–421.
14. Walther G, Wagner L, Kurzai O. Updates on the taxonomy of mucorales with an emphasis on clinically important taxa. *J Fungi.* 2019;5(4). doi: 10.3390/jof5040106
15. Prakash H, Chakrabarti A. Global epidemiology of mucormycosis. *J Fungi.* 2019;5(1):26. doi: 10.3390/jof5010026
16. Prakash H, Chakrabarti A. Epidemiology of mucormycosis in India. *Microorganisms.* 2021;9(3):1–12.
17. Lanternier F, Dannaoui E, Morizot G, et al. A global analysis of mucormycosis in France: The RetroZygo study (2005-2007). *Clin Infect Dis.* 2012;54(Suppl 1):S35–S43.
18. Guinea J, Escribano P, Vena A, et al. Increasing incidence of mucormycosis in a large Spanish hospital from 2007 to 2015: Epidemiology and microbiological characterization of the isolates. *PLoS One.* 2017;12(6):1–10. doi.org/10.1371/journal.pone.0229347
19. Richardson M. The ecology of the zygomycetes and its impact on environmental exposure. *Clin Microbiol Infect.* 2009;15(Suppl 5):S2–S9. doi.org/10.1111/j.1469-0691.2009.02972.x
20. Prakash H, Ghosh A, Rudramurthy S, et al. The environmental source of emerging *Apophysomyces variabilis* infection in India. *Med Mycol.* 2016;54(6):567–575.
21. Prakash H, Singh S, Rudramurthy SM, et al. An aero mycological analysis of *Mucormycetes* in indoor and outdoor environments of northern India. *Med Mycol.* 2020;58(1):118–123.
22. Caetano LA, Faria T, Springer J, et al. Antifungal-resistant *Mucorales* in different indoor environments. *Mycology.* 2019;10(2):75–83. /doi.org/10.1080/21501203.2018.1551251
23. Rammaert B, Lanternier F, Zahar JR, et al. Healthcare-associated mucormycosis. *Clin Infect Dis.* 2012;54 (Suppl 1): S44-S54.
24. Cериello A. Hyperglycemia and COVID-19: What was known and what is really new?. *Diabetes Res Clin Pract.* 2020;167:108383.doi:10.1016/j.diabres.2020.108383

25. Skiada A, Pavleas I, Drogari-Apiranthitou M. Epidemiology and diagnosis of mucormycosis: An update. *J Fungi*. 2020;6(4):265. doi: 10.3390/jof6040265
26. Oriot P, Hermans MP. Euglycemic diabetic ketoacidosis in a patient with type 1 diabetes and SARS-CoV-2 pneumonia: case report and review of the literature. *Acta Clin Belgica Int J Clin Lab Med*. 2020;16:1–5. doi.org/10.1080/17843286.2020.1780390
27. Li X, Xu S, Yu M, et al. Risk factors for severity and mortality in adult COVID-19 inpatients in Wuhan. *J Allergy Clin Immunol*. 2020;146(1):110–118. doi.org/10.1016/j.jaci.2020.04.006
28. Yang JK, Lin SS, Ji XJ, Guo LM. Binding of SARS coronavirus to its receptor damages islets and causes acute diabetes. *Acta Diabetol*. 2010;47(3):193–199.
29. Müller JA, Groß R, Conzelmann C, et al. SARS-CoV-2 infects and replicates in cells of the human endocrine and exocrine pancreas. *Nat Metab*. 2021;3(2):149–165. doi.org/10.1038/s42255-021-00347-1
30. Kothandaraman N, Anantharaj R, Xue B, et al. COVID-19 Endocrinopathy with hindsight from SARS. *Am J Physiol - Endocrinol Metab*. 2021;320(1):e139-150.
31. Vitale RJ, Valtis YK, McDonnell ME, et al. Euglycemic Diabetic Ketoacidosis With COVID-19 Infection in Patients With Type 2 Diabetes Taking SGLT2 Inhibitors. *ACE Clin Case Reports*. 2021;7(1):10–13. doi.org/10.1016/j.ace.2020.11.019
32. Morales-Franco B, Nava-Villalba M, Medina-Guerrero EO, et al. Host-Pathogen Molecular Factors Contribute to the Pathogenesis of *Rhizopus* spp. in Diabetes Mellitus. *Curr Trop Med Reports*. 2021;8(1):6–17.
33. Tamez-Pérez HE. Steroid hyperglycemia: Prevalence, early detection and therapeutic recommendations: A narrative review. *World J Diabetes*. 2015;6(8):1073-1081.
34. Boumpas DT, Chrousos GP, Wilder RL, et al. Glucocorticoid therapy for immune-mediated diseases: Basic and clinical correlates. *Ann Intern Med*. 1993;119(12):1198–1208.
35. Youssef J, Novosad SA, Winthrop KL. Infection Risk and Safety of Corticosteroid Use. *Rheum Dis Clin North Am*. 2016;42(1):157–176. doi.org/10.1016/j.rdc.2015.08.004
36. Ibrahim AS, Spellberg B, Walsh TJ, Kontoyiannis DP. Pathogenesis of mucormycosis. *Clin Infect Dis*. 2012;54(Suppl 1):S16 - S22
37. Gómez-Pastora J, Weigand M, Kim J, et al. Hyperferritinemia in critically ill COVID-19 patients – Is ferritin the product of inflammation or a pathogenic mediator? *Clin Chim*

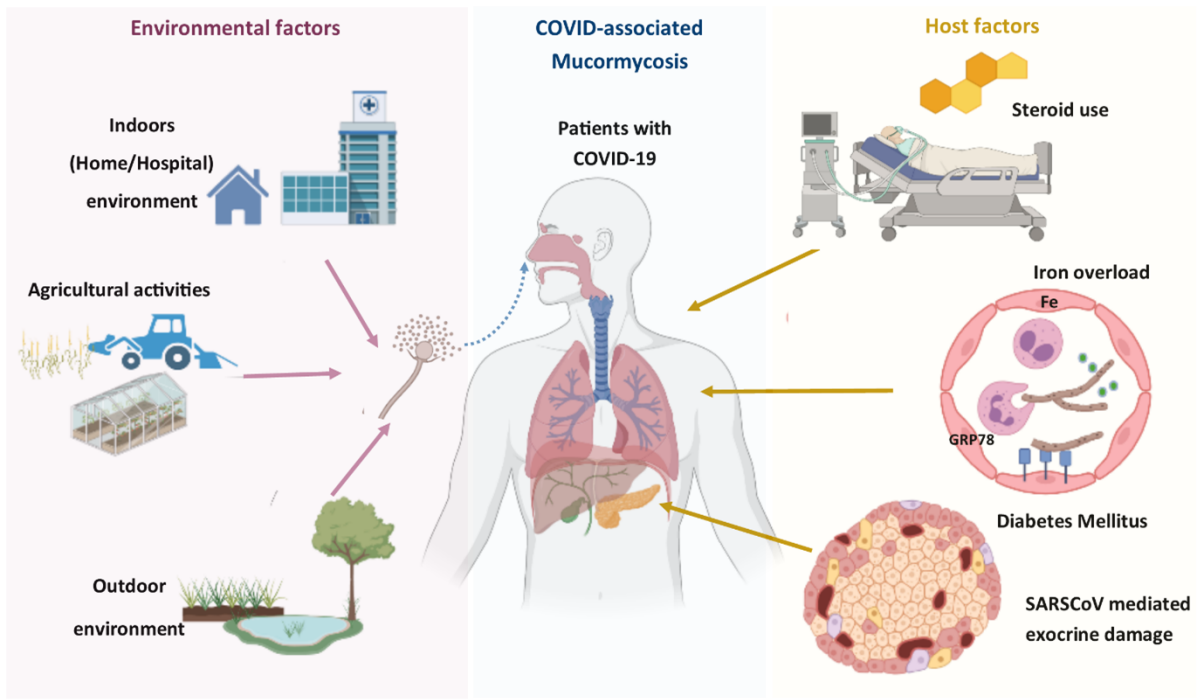
*Acta.* 2020;509:249–251.

38. Perricone C, Bartoloni E, Bursi R, et al. COVID-19 as part of the hyperferritinemic syndromes: the role of iron depletion therapy. *Immunol Res.* 2020;68(4):213–224.
39. Edeas M, Saleh J, Peyssonnaud C. Iron: Innocent bystander or vicious culprit in COVID-19 pathogenesis? *Int J Infect Dis.* 2020;97:303–305. doi.org/10.1016/j.ijid.2020.05.110
40. Ackermann M, Verleden SE, Kuehnel M, et al. Pulmonary Vascular Endothelialitis, Thrombosis, and Angiogenesis in Covid-19. *N Engl J Med.* 2020;383(2):120–128.
41. Lim S, Bae JH, Kwon HS, Nauck MA. COVID-19 and diabetes mellitus: from pathophysiology to clinical management. *Nature Rev Endocrinol.* 2021;17:11–30.
42. Liu M, Spellberg B, Phan QT, et al. The endothelial cell receptor GRP78 is required for mucormycosis pathogenesis in diabetic mice. *J Clin Invest.* 2010;120(6):1914–1924.
43. Gebremariam T, Liu M, Luo G, et al. CoH3 mediates fungal invasion of host cells during mucormycosis. *J Clin Invest.* 2014;124(1):237–250.
44. Sabirli R, Koseler A, Goren T, et al. High GRP78 levels in Covid-19 infection: A case-control study. *Life Sci.* 2021;265:118781. doi: 10.1016/j.lfs.2020.118781.
45. Zaman K, Rudramurthy SM, Das A, et al. Molecular diagnosis of rhino-orbito-cerebral mucormycosis from fresh tissue samples. *J Med Microbiol.* 2017;66(8):1124–1129.
46. Jillwin J, Rudramurthy SM, Singh S, et al. Molecular identification of pathogenic fungi in formalin-fixed and paraffin-embedded tissues. *J Med Microbiol.* 2020;70(2). doi: 10.1099/jmm.0.001282.
47. Pandey M, Xess I, Singh G, et al. Conventional PCR as a reliable method for diagnosing invasive mucormycosis in resource-limited settings. *J Med Microbiol.* 2021;70(5). doi: 10.1099/jmm.0.001370.
48. Skiada A, Lass-Floerl C, Klimko N, et al.. Challenges in the diagnosis and treatment of mucormycosis. *Med Mycol.* 2018;56:S93–101.
49. Guegan H, Iriart X, Bougnoux ME, et al. Evaluation of MucorGenius® mucorales PCR assay for the diagnosis of pulmonary mucormycosis. *J Infect.* 2020;81(2):311–317. doi.org/10.1016/j.jinf.2020.05.051.
50. Chamilos G, Lewis RE, Kontoyiannis DP. Delaying amphotericin B-based frontline therapy significantly increases mortality among patients with hematologic malignancy who have zygomycosis. *Clin Infect Dis.* 2008;47(4):503–509.
51. Fungal Infections Study Forum. Treatment of Covid associated mucormycosis. 2021.

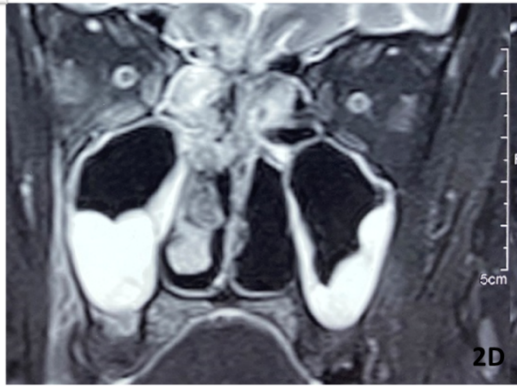
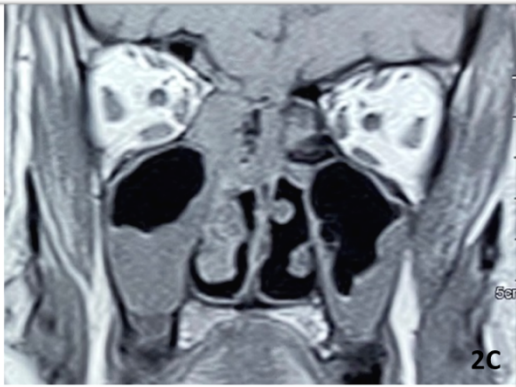
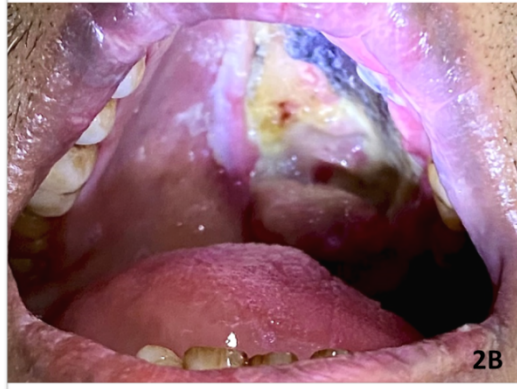
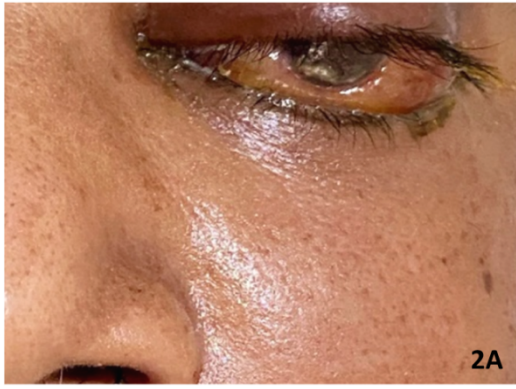<http://www.fisftrust.org/covid-19/Asscoiated-Mucormycosis/images/Treatment-CAM-20-5-21.pdf> (last accessed 8 June 2021)

52. Ganesh R, Manikumar S, Vasanthi T. Rhinocerebral mucormycosis in an adolescent with type 1 diabetes mellitus: Case report. *Ann Trop Paediatr*. 2008;28(4):297–300.
53. Quinio D, Karam A, Leroy JP, et al. Zygomycosis caused by *Cunninghamella bertholletiae* in a kidney transplant recipient. *Med Mycol*. 2004;42(2):177–80.
54. Venkatachalam VP, Anand N. Paranasal mucormycosis: Unusual presentation in otherwise healthy child. *Indian J Otolaryngol Head Neck Surg*. 2007;59(3):264–266.
55. Patel A, Kaur H, Xess I, et al. A multicentre observational study on the epidemiology, risk factors, management and outcomes of mucormycosis in India. *Clin Microbiol Infect*. 2020;26(7):944.e9-944.e15. doi.org/10.1016/j.cmi.2019.11.021
56. Espinel-Ingroff A, Chakrabarti A, Chowdhary A, et al. Multicenter evaluation of MIC distributions for epidemiologic cutoff value definition to detect amphotericin B, posaconazole, and itraconazole resistance among the most clinically relevant species of *Mucorales*. *Antimicrob Agents Chemother*. 2015;59(3):1745–1750.

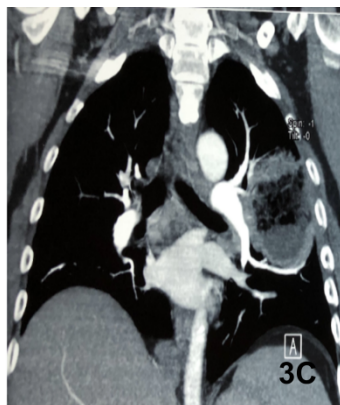
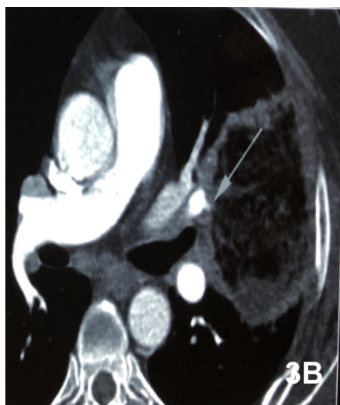
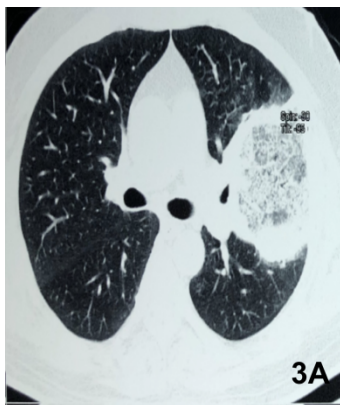




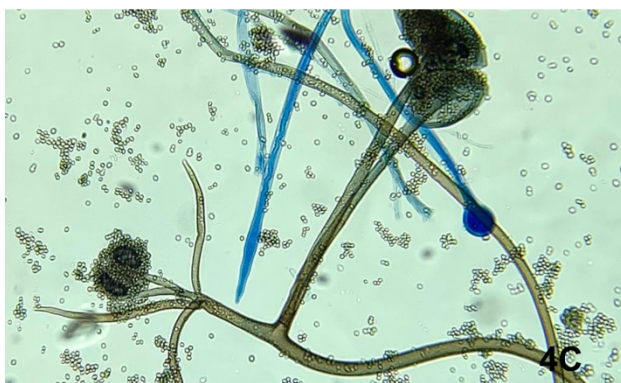
myc\_13335\_f1.tif



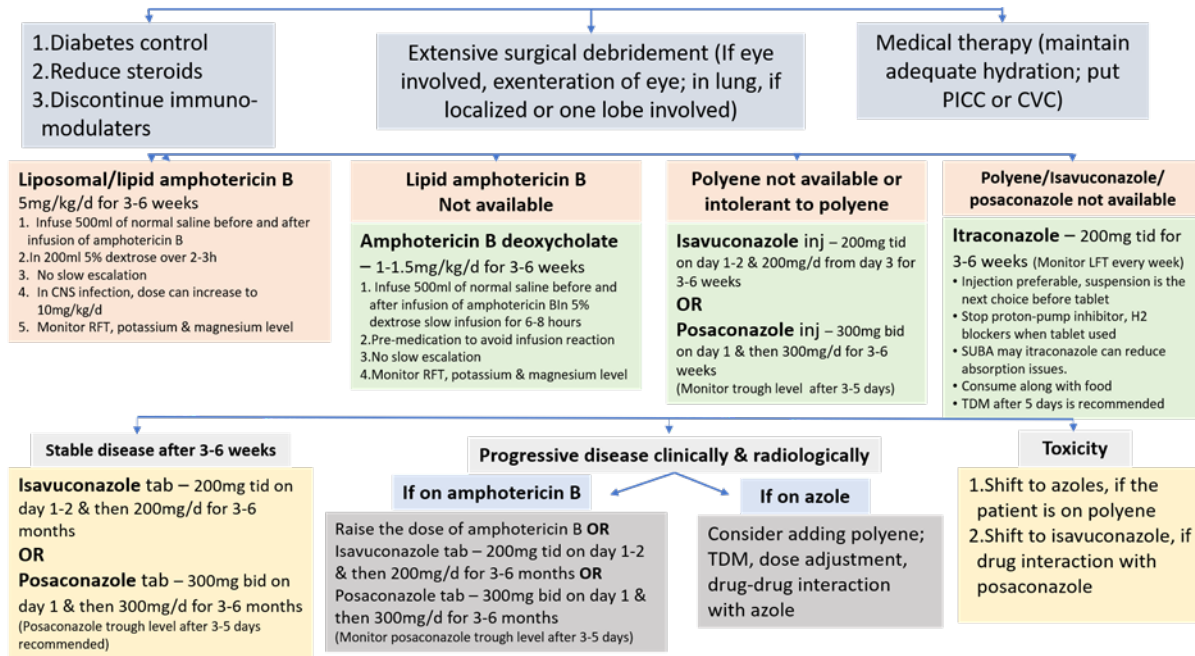
myc\_13335\_f2.tif



myc\_13335\_f3.tif



myc\_13335\_f4.tif



myc\_13335\_f5.tif





## Do's

- **Maintain strict glycaemic control** during COVID-19 management.
- **Systemic corticosteroids should only be used in patients with hypoxemia** while ensuring glycaemic control.
- **Limit the dose and duration of steroid** therapy: dexamethasone (0.1mg/kg/day) for 5-10 days.
- **Use of surgical or three-layered linen mask**, both outdoor and indoor to reduce exposure to *Mucorales*.
- Advise all patients especially diabetics to **check for early signs of mucormycosis** (facial pain, nasal blockage, excessive discharge, loosening of teeth, chest pain, respiratory insufficiency) after discharge from COVID-19 wards.



## Don'ts

- **Primary antifungal prophylaxis is not recommended** for diabetes associated mucormycosis including CAM.
- *Mucorales* are **intrinsically resistant to voriconazole, fluconazole, caspofungin, anidulafungin, micafungin, and 5-fluorocytosine**. These drugs are not effective against mucormycosis and should not be used for treatment.
- **Breakthrough mucormycosis** is common with **voriconazole prophylaxis**.
- **Combination of antifungals is NOT recommended** for treating CAM.



### Remember:

- The term '**Black Fungi**' should **NOT** be used for *Mucorales* or for the disease 'mucormycosis'. 'Black fungi' are a different group of fungi that produce melanin and have dark brown or black hyphae.
- Mucormycosis is **NOT contagious**. Human to human transmission does not occur.
- **Fungi are present in the indoor & outdoor environment** and spores enter the respiratory tract via air.
- **No antifungal prophylaxis** is recommended as the incidence is <10% in any COVID-19 cohort.