



## Arterial and venous abdominal thrombosis in a 79-year-old woman with COVID-19 pneumonia

Olivier de Barry, Ahmed Mekki, Caroline Diffre, Martin Seror, Mostafa El Hajjam, Robert Yves Carlier

### ► To cite this version:

Olivier de Barry, Ahmed Mekki, Caroline Diffre, Martin Seror, Mostafa El Hajjam, et al.. Arterial and venous abdominal thrombosis in a 79-year-old woman with COVID-19 pneumonia. Radiology Case Reports, 2020, 15 (7), pp.1054-1057. 10.1016/j.radcr.2020.04.055 . hal-02677114

**HAL Id: hal-02677114**

**<https://hal.science/hal-02677114>**

Submitted on 3 Jun 2020

**HAL** is a multi-disciplinary open access archive for the deposit and dissemination of scientific research documents, whether they are published or not. The documents may come from teaching and research institutions in France or abroad, or from public or private research centers.

L'archive ouverte pluridisciplinaire **HAL**, est destinée au dépôt et à la diffusion de documents scientifiques de niveau recherche, publiés ou non, émanant des établissements d'enseignement et de recherche français ou étrangers, des laboratoires publics ou privés.



Distributed under a Creative Commons Attribution - NonCommercial - NoDerivatives 4.0 International License

Available online at [www.sciencedirect.com](http://www.sciencedirect.com)

ScienceDirect

journal homepage: [www.elsevier.com/locate/radcr](http://www.elsevier.com/locate/radcr)

## Case Report

# Arterial and venous abdominal thrombosis in a 79-year-old woman with COVID-19 pneumonia ☆☆☆

Olivier de Barry, Medical intern<sup>a,b,\*</sup>, Ahmed Mekki, MD<sup>a,b</sup>, Caroline Diffre, MD<sup>a,b</sup>, Martin Seror, MD<sup>a</sup>, Mostafa El Hajjam, MD<sup>a</sup>, Robert-Yves Carlier, MD<sup>a,b,c</sup>

<sup>a</sup> DMU Smart Imaging, Medical Imaging Department, Assistance Publique-Hôpitaux de Paris, GH Université Paris-Saclay, Ambroise Paré Teaching Hospital, 9 Avenue Charles de Gaulle, 92100 Boulogne-Billancourt, France

<sup>b</sup> DMU Smart Imaging, Medical Imaging department, Assistance Publique-Hôpitaux de Paris, GH Université Paris-Saclay, Raymond Poincaré Teaching Hospital, Garches, France

<sup>c</sup> UMR 1179 End-icap, Université Versailles Saint-Quentin-en-Yvelines/Paris-Saclay, Versailles, France

## ARTICLE INFO

## Article history:

Received 16 April 2020

Revised 21 April 2020

Accepted 21 April 2020

Available online 29 April 2020

## Keywords:

COVID-19

coronavirus

CT scan

Severe acute respiratory syndrome

coronavirus 2

Thrombosis

## ABSTRACT

As coronavirus pandemic continue to spread over the world, we have to be aware of potential complications on hospitalized patients. We report a case of a 79-year-old woman with COVID-19 pneumonia complicated by combined arterial and venous thrombosis of upper mesenteric vessels. As unenhanced chest CT scan plays a key role in managing the COVID-19 pandemic, we should pay attention to indirect signs of thrombosis.

© 2020 The Authors. Published by Elsevier Inc. on behalf of University of Washington.

This is an open access article under the CC BY-NC-ND license.

(<http://creativecommons.org/licenses/by-nc-nd/4.0/>)

## Introduction

Coronavirus disease (COVID-19), a highly infectious disease caused by severe acute respiratory syndrome coronavirus 2 (SARS-CoV-2), was first reported in Wuhan, Hubei Province, China, and rapidly spread to other domestic cities and many countries beyond China. Since chest CT scans are crucial for

the diagnosis and management of COVID-19 patients [1], our activity as radiologists has changed drastically with the number of nonenhanced chest tomodensitometry increasing significantly [2]. Pulmonary manifestations are now widely described but few relate about abdominal and thromboembolic complications apart from pulmonary embolism. We report the imaging features of simultaneous arterial and venous throm-

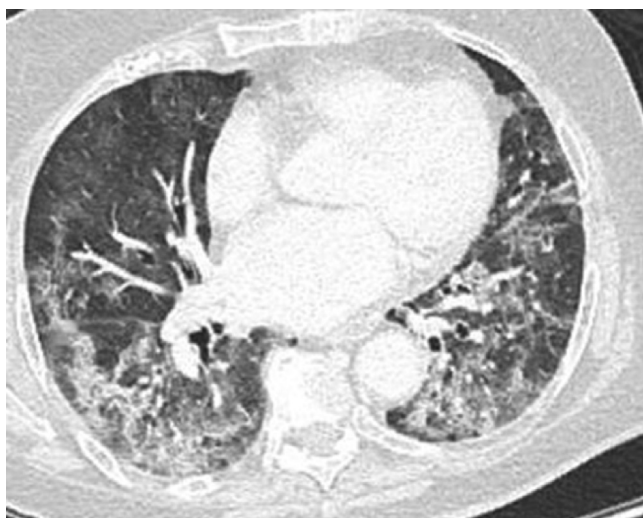
☆ Funding: None.

☆☆ Declaration of Competing Interest: Authors declare that they have no competing interest.

\* Corresponding author.

E-mail addresses: [olivier.debarry@aphp.fr](mailto:olivier.debarry@aphp.fr) (O. de Barry), [ahmed.mekki@aphp.fr](mailto:ahmed.mekki@aphp.fr) (A. Mekki), [caroline.diffre@aphp.fr](mailto:caroline.diffre@aphp.fr) (C. Diffre), [martin.seror@aphp.fr](mailto:martin.seror@aphp.fr) (M. Seror), [mostafa.elhajjam@aphp.fr](mailto:mostafa.elhajjam@aphp.fr) (M. El Hajjam), [robert.carlier@aphp.fr](mailto:robert.carlier@aphp.fr) (R.-Y. Carlier).  
<https://doi.org/10.1016/j.radcr.2020.04.055>

1930-0433/© 2020 The Authors. Published by Elsevier Inc. on behalf of University of Washington. This is an open access article under the CC BY-NC-ND license. (<http://creativecommons.org/licenses/by-nc-nd/4.0/>)



**Fig. 1 – COVID-19 pneumonia.** Transverse section of unenhanced chest CT scans showing typical lesions of COVID-19 pneumonia: ground glass associated with consolidation and intralobular lines, sometimes arcuate, with peripheral and declining predominance.

basis in a 79-year-old patient affected by COVID-19-induced pneumonia.

### Clinical and radiologic observation

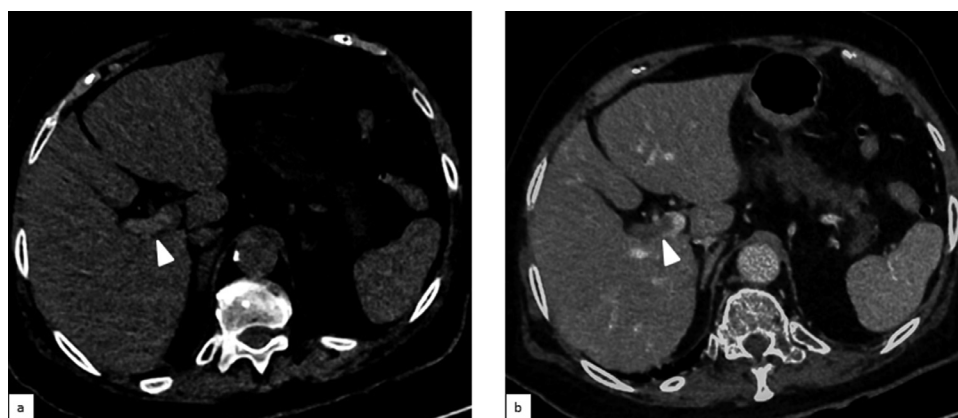
A 79-year-old woman, without known medical history, was suffering from fever, deterioration of her general condition, and abdominal pain located in the epigastric area associated with diarrhea over the previous 8 days. As acute dyspnea added to its symptoms, she went to the emergency room. Initially, the patient was hemodynamically stable (Blood pressure: 168/89 mm Hg), showed symptoms of acute respiratory

insufficiency with polypnea (22 cycles per minutes with 86% of blood oxygen saturation in ambient air), and tachycardia (100 bpm). Blood tests revealed C-reactive protein (125 mg/L) increase and a hyperleukocytosis ( $12,600/\text{mm}^3$ ) with lymphopenia. Blood gas analysis showed compensated lactic acidosis (pH 7.43 with hyperlactatemia: 5.36 mmol/L). Nasopharynx PCR was negative for SARS-CoV-2.

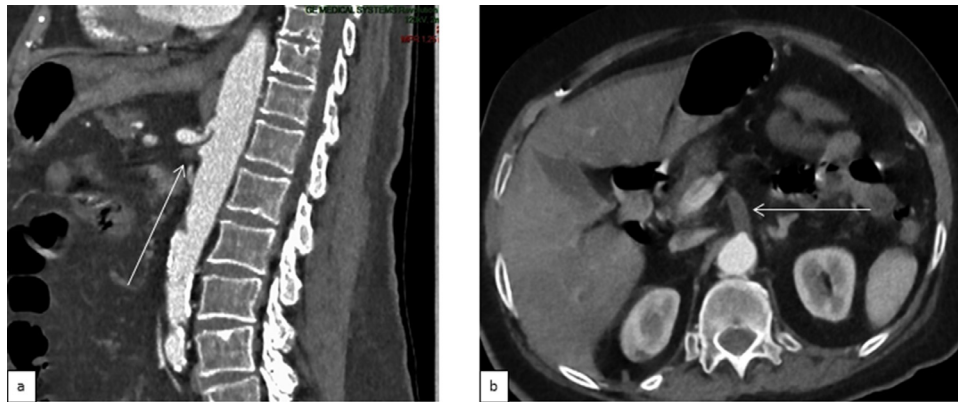
Two hours after admission, an unenhanced chest CT scan displayed typical signs of COVID-19 pneumonia [13] (mostly ground-glass opacity without CT-backed evidence of another infection) with critical extent ( $>75\%$  of pulmonary parenchyma; Fig. 1). The upper abdominal slices showed a spontaneous hyperdensity (71 Hounsfield units (HU) vs 38 HU in the portal vein) in the right portal vein (Figs. 2a and 4b). Further examination with enhanced CT scan of the chest, abdomen, and pelvis at the arterial and portal phases, performed at the same time, confirmed a right-portal vein thrombosis (Fig. 2b) originating from thrombosis of the distal part of the upper mesenteric vein extended to the spleno-mesaraic trunk. A proximal thrombosis of the upper mesenteric artery (Figs. 3a and b) and jejunal artery were also observed with subsequent features of bowel ischemia of the caecum and small intestine (Figs. 4a and b) with small amount of liquid in the peritoneal cavity. No pulmonary embolism was revealed. Laparotomy was undertaken few hours later and confirmed ischemia, where a meter of necrotic ileum and right colon were removed. Thrombolysis and thrombectomy of the upper mesenteric artery were also performed during the same procedure. Despite timely treatment, his medical condition stayed precarious because of extended bowel ischemia in addition to severe lung damage caused by COVID-19. Palliative cares was implemented and the patient passed away 4 days later.

### Discussion

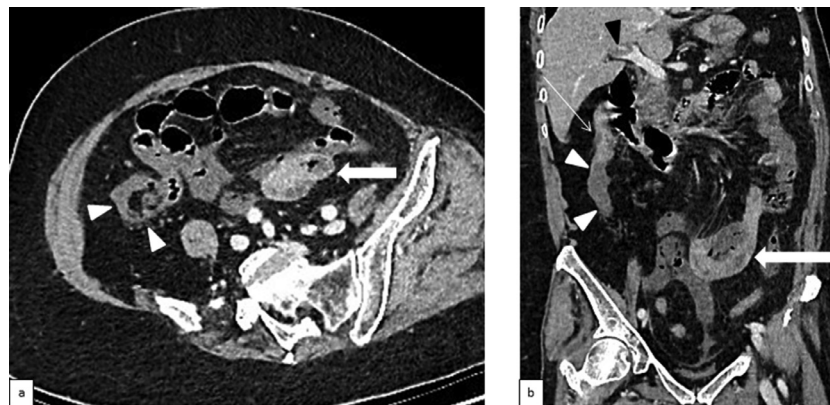
COVID 19 is associated with a large and misleading field of symptoms [3] and complications including coagulopathy [4] as



**Fig. 2 – Imaging features of venous thromboembolic disease in a 79-year-old COVID-19 patient.** a: Native transverse upper abdominal slice of the unenhanced chest CT scan showing a spontaneous hyperdensity in the right portal vein (white arrowhead). b: Native transverse portal abdominal CT scan image showing an intraluminal thrombus of the right portal vein (white arrowhead).



**Fig. 3** – Imaging features of arterial thromboembolic disease in a 79-year-old COVID-19 patient. a: Sagittal reconstruction of arterial abdominal CT scan showing a thrombotic ostial occlusion of the upper mesenteric artery (thin arrow). b: Native transverse arterial abdominal CT scan image showing a thrombotic ostial occlusion of the upper mesenteric artery (thin arrow).



**Fig. 4** – Imaging features of bowel ischemia in a 79-year-old COVID-19 patient. a: Oblique transverse reconstruction of portal abdominal CT scan. b: Oblique coronal reconstruction of portal abdominal CT scan image. Both images show a perfusion defect of the right large intestine—lower and middle third including caecum—(white arrowheads) relative to a normal loop of the small intestine (large white arrows) and a normal upper of the right large intestine (thin white arrow). Right-portal vein thrombosis can also be seen (black arrowhead).

often seen in acute infection [5] including Influenza [6]. This hypercoagulation status, which results in diseases such as pulmonary embolism [7–9], is leading learned societies to ask themselves the question of an anticoagulation therapy at prophylaxis dose or even higher [10,11]. Gastrointestinal symptoms reported with COVID-19 are not specific and include nausea, vomiting, diarrhea, and raised liver enzyme [12].

In our case, Nasopharynx PCR was negative for SARS-CoV-2 although CT scan displayed typical signs of COVID-19 pneumonia. This scenario is frequently reported [1] and do not disprove the diagnosis.

As known, chest CT scan is an essential exam for the diagnosis, evaluation of extension and care management mostly in nonambulatory patients. Moreover, it could help in patient follow-up with worsening clinical conditions.

When CT scan control is needed, it seems reasonable to perform whole body enhanced CT scan at arterial and venous phases especially in case of pulmonary embolism suspicion or abdominal pain.

## Conclusion

Chest CT scan is essential in managing the COVID-19 pandemic and allows to uncover potential complications such as thromboembolic diseases. Close attention should be paid to indirect signs of thrombosis on unenhanced CT scan.

## REFERENCES

- [1] Ai Tao, Yang Zhenlu, Hou Hongyan, Zhan Chenao, Chen Chong, Lv Wenzhi, et al. Correlation of chest CT and RT-PCR testing in coronavirus disease 2019 (COVID-19) in China: a report of 1014 cases. *Radiology* 2020. doi:[10.1148/radiol.2020200642](https://doi.org/10.1148/radiol.2020200642).
- [2] Kim Hyungjin. Outbreak of novel coronavirus (COVID-19): what is the role of radiologists? *Eur Radiol* 2020. doi:[10.1007/s00330-020-06748-2](https://doi.org/10.1007/s00330-020-06748-2).
- [3] Zhou Min, Zhang Xinxin, Qu Jieming. Coronavirus disease 2019 (COVID-19): a clinical update. *Front Med* 2020. doi:[10.1007/s11684-020-0767-8](https://doi.org/10.1007/s11684-020-0767-8).
- [4] Zhang Y, Cao W, Xiao M, Li YJ, Yang Y, Zhao J, et al. Clinical and coagulation characteristics of 7 patients with critical COVID-2019 pneumonia and acro-ischemia. *Zhonghua Xue Ye Xue Za Zhi* 2020;41(0):E006. doi:[10.3760/cma.j.issn.0253-2727.2020.0006](https://doi.org/10.3760/cma.j.issn.0253-2727.2020.0006).
- [5] Smeeth Liam, Cook Claire, Thomas Sara, J Hall Andrew, Hubbard Richard, Vallance Patrick. Risk of deep vein thrombosis and pulmonary embolism after acute infection in a community setting. *Lancet* 2006. doi:[10.1016/S0140-6736\(06\)68474-2](https://doi.org/10.1016/S0140-6736(06)68474-2).
- [6] Yang Yan, Tang Hong. Aberrant coagulation causes a hyper-inflammatory response in severe influenza pneumonia. *Cell Mol Immunol* 2016;13:432–42. doi:[10.1038/cmi.2016.1](https://doi.org/10.1038/cmi.2016.1).
- [7] Danzi Gian Battista, Loffi Marco, Galeazzi Gianluca, Gherbesi Elisa. Acute pulmonary embolism and COVID-19 pneumonia: a random association? *Eur Heart J* 2020. doi:[10.1093/eurheartj/ehaa254](https://doi.org/10.1093/eurheartj/ehaa254).
- [8] Fabre Olivier, Rebet Olivier, Carjaliu Ionut, Radutoiu Mihai, Gautier Laurence, Hysi Illir. Severe acute proximal pulmonary embolism and COVID-19: a word of caution. *Ann Thorac Surg* 2020. doi:[10.1016/j.athoracsur.2020.04.005](https://doi.org/10.1016/j.athoracsur.2020.04.005).
- [9] Cellina M, Oliva G. Acute pulmonary embolism in a patient with COVID-19 pneumonia. *Diagn Interv Imaging* 2020. doi:[10.1016/j.diii.2020.04.001](https://doi.org/10.1016/j.diii.2020.04.001).
- [10] Tang Ning, Bai Huan, Chen Xing, Gong Jiale, Li Dengju, Sun Ziyong. Anticoagulant treatment is associated with decreased mortality in severe coronavirus disease 2019 patients with coagulopathy. *J Thromb Haemost* 2020. Accepted Author Manuscript. doi:[10.1111/jth.14817](https://doi.org/10.1111/jth.14817).
- [11] Marietta Marco, Ageno Walter, Artoni Andrea, De Candia Erica, Gresele Paolo, Marchetti Marina, et al. COVID-19 and haemostasis: a position paper from Italian Society on Thrombosis and Haemostasis (SISIT). *Blood Transfus* 2020. doi:[10.2450/2020.0083-20](https://doi.org/10.2450/2020.0083-20).
- [12] Wong Sunny H, Lui Rashid NS, Sung Joseph JY. Covid-19 and the digestive system. *J Gastroenterol Hepatol* 2020. doi:[10.1111/jgh.15047](https://doi.org/10.1111/jgh.15047).
- [13] Ye Zheng, Zhang Yun, Wang Yi, Zixiang Huang, Bin Song. Chest CT manifestations of new coronavirus disease 2019 (COVID-19): a pictorial review. *Eur Rad* 2020. doi:[10.1007/s00330-020-06801-0](https://doi.org/10.1007/s00330-020-06801-0).