



Outcomes of capsulolabral reconstruction for posterior shoulder instability

Kevin Andrieu, Johannes Barth, Mo Saffarini, Philippe Clavert, Arnaud Godenèche, Pierre Mansat

► To cite this version:

Kevin Andrieu, Johannes Barth, Mo Saffarini, Philippe Clavert, Arnaud Godenèche, et al.. Outcomes of capsulolabral reconstruction for posterior shoulder instability. *Orthopaedics & Traumatology: Surgery & Research*, 2017, 103 (8), pp.S189-S192. 10.1016/j.otsr.2017.08.002 . hal-02135076

HAL Id: hal-02135076

<https://hal.science/hal-02135076>

Submitted on 21 May 2019

HAL is a multi-disciplinary open access archive for the deposit and dissemination of scientific research documents, whether they are published or not. The documents may come from teaching and research institutions in France or abroad, or from public or private research centers.

L'archive ouverte pluridisciplinaire **HAL**, est destinée au dépôt et à la diffusion de documents scientifiques de niveau recherche, publiés ou non, émanant des établissements d'enseignement et de recherche français ou étrangers, des laboratoires publics ou privés.



Open Archive Toulouse Archive Ouverte (OATAO)

OATAO is an open access repository that collects the work of some Toulouse researchers and makes it freely available over the web where possible.

This is an author's version published in: <https://oatao.univ-toulouse.fr/23105>

Official URL : <https://doi.org/10.1016/j.otsr.2017.08.002>

To cite this version :

Andrieu, Kevin and Barth, Johannes and Saffarini, Mo and Clavert, Philippe and Godenèche, Arnaud and Mansat, Pierre ➡ *Outcomes of capsulolabral reconstruction for posterior shoulder instability*. (2017) *Orthopaedics & Traumatology: Surgery & Research*, 103 (8). S189-S192. ISSN 1877-0568

Any correspondence concerning this service should be sent to the repository administrator:

tech-oatao@listes-diff.inp-toulouse.fr

Outcomes of capsulolabral reconstruction for posterior shoulder instability

K. Andrieu^{a,*}, J. Barth^b, M. Saffarini^c, P. Clavert^d, A. Godenèche^e, P. Mansat^f,
the French Arthroscopy Society

^a Hôpital Universitaire de Nantes, 44000 Nantes, France

^b Clinique des cèdres d'Échirolles, 38130 Échirolles, France

^c Nyon, Switzerland

^d Hôpital Universitaire de Strasbourg, 67400 Strasbourg, France

^e Clinique Santy, 69008 Lyon, France

^f Hôpital Universitaire de Toulouse, 31000 Toulouse, France

ABSTRACT

Keywords:

Shoulder instability

Posterior

Capsulolabral reconstruction

Background: Surgical treatment of isolated posterior shoulder instability—a rare and often misdiagnosed condition—is controversial because of poor outcomes. Failure of physical therapy in symptomatic young athletes requires capsulolabral reconstruction or bone block procedures. The goal of this study was to report the outcomes of patients who have undergone surgical capsulolabral reconstruction and to look for risk factors that contribute to failure of this procedure.

Material and method: We analyzed the outcomes of 101 patients who underwent capsulolabral reconstruction: 83 included retrospectively, 18 included prospectively. The procedures were performed alone or in combination with capsular shift, labral repair, closure of the rotator interval and notch remplissage. The primary endpoint was failure of the procedure, defined as recurrence of the instability and/or pain. We also determined the outcomes based on specific (Walch–Duplay, modified Rowe) and non-specific (Constant, resumption of activities) scores of shoulder instability.

Results: The results were satisfactory despite a high failure rate: 35% in the retrospective cohort with 4.8 ± 2.6 years' follow-up and 22% in the prospective cohort with 1.1 ± 0.3 years' follow-up. The various outcome scores improved significantly. Ninety-two percent of patients returned to work and 80% of athletes returned to their pre-injury level of sports. Eighty-five percent of patients were satisfied or very satisfied after the surgery. No risk factors for failure were identified; however, failures were more common in older patients, those who underwent an isolated procedure and those who had unclassified clinical forms.

Conclusion: Treatment of posterior shoulder instability by capsulolabral reconstruction leads to good clinical outcomes; however, the recurrence rate is high.

Level of evidence: 4 – retrospective study.

1. Introduction

Treatment of posterior shoulder instability continues to be challenging. This is a rare condition that makes up 2% to 10% of shoulder instability cases [1,2] and mainly affects young, male athletes [3,4]. The main risk factors for recurrence [4] are being less than 40 years of age, suffering from epilepsy and having a humeral notch volume greater than 1.5 cm^3 . Surgical techniques to enhance shoulder stability have improved with the development of arthroscopy [5–8].

They are now more reproducible and have limited complications related to posterior shoulder approaches [9,10].

Surgical techniques for posterior instability resemble those for anterior instability but the published outcomes are not as good [3,11]. The diagnosis can be difficult to make as other injuries may be present concurrently in the shoulder. These must be ruled out, otherwise the treatment provided will be inappropriate, potentially leading to poor outcomes [12].

There are no large published French studies on the outcomes after surgical capsulolabral reconstruction for isolated posterior shoulder instability. Large studies from the United States [7,13,14] focus on athletes involved in pitching sports.

Clinical examination must discover four main criteria to define instability: unidirectional posterior subluxation [15], voluntary or

☆ * Corresponding author.

E-mail address: andkevin@hotmail.com (K. Andrieu).

involuntary and reproducible [14], presence of hyperlaxity and a defined injury event. A full imaging work-up consisting of X-rays, CT scan or MRI with injection is needed to identify bone, capsule and labrum injuries. It will also reveal any cartilage damage that may be contributing to the pain, which often occurs with instability [7].

The goal of this study was to determine the outcomes of patients who have undergone isolated soft tissue procedures (labral repair, capsular reconstruction and/or tendon/ligament repair) as a treatment for isolated posterior shoulder instability and to identify risk factors for failure. We hypothesized the best results would be obtained in athletic patients who have involuntary post-traumatic instability without associated bone damage.

2. Material and methods

In the context of a symposium of the Francophone Society of Arthroscopy (SFA) on posterior shoulder instability, we included 202 patients treated for isolated posterior shoulder instability at 11 hospitals. The cohort consisted of 150 patients included retrospectively and 52 patients included prospectively.

Inclusion criteria were the presence of unidirectional posterior instability, with or without pain, surgical treatment on the soft tissues and at least 1 year of follow-up. Patients were excluded if they had undergone a bone block procedure (15 in the prospective cohort and 66 in the retrospective cohort), if they had not been treated surgically (19 in the prospective cohort), had a psychological condition related to the instability, or had posterior subluxation with osteoarthritis or chronic dislocation.

The procedures performed consisted of capsular shifting (10 in the retrospective cohort and 3 in the prospective one), capsulolabral reconstruction (6 in the retrospective cohort and 1 in the prospective one) as described by Bradley et al. [15] or a combination of both (62 in the retrospective cohort and 13 in the prospective cohort) with associated rotator interval closure in select cases (8 in retrospective cohort). For 7 patients in the retrospective cohort and 3 in the prospective cohort, anterior notch remplissage was performed alone or in combination with other procedures.

Data were collected from the preoperative records and at the last follow-up for patients in the retrospective cohort. For the patients in the prospective cohort, data were collected before the surgery and then at 6 and 12 months' postoperative. The clinical outcomes consisted of specific (Walch–Duplay, modified Rowe) and non-specific (VAS for pain, Constant, Subjective Shoulder Value) scores of shoulder instability. Every patient also underwent X-rays and CT arthrography or MRI to look for capsule, labrum and bone damage.

Patients were placed in one of four groups, depending on the clinical presentation:

- involuntary for patients with instability secondary to a defined injury event, without reproducible or voluntary dislocation;
- voluntary for patients with reproducible voluntary instability, typically without a defined injury event, but with inherent hyperlaxity;
- voluntary to involuntary for patients with voluntary instability initially who suffered an injury leading to loss of control over their instability, which is now symptomatic;
- pain for patients who complain of pain with anatomical posterior instability lesions.

The primary endpoint was the occurrence of failure, defined as recurrence of the instability with dislocation or subluxation and/or pain. The secondary endpoints were the Walch–Duplay and modified Rowe Shoulder Specific scores [16,17], Visual Analog Scale (VAS) for pain, Subjective Shoulder Value (SSV) and Constant scores. Patient satisfaction was graded as very satisfied, satisfied,

somewhat satisfied and disappointed. Return to work and resumption of sports were also recorded.

Statistical analysis: descriptive statistics were used to summarize the data. The normality of the distributions was verified using the Shapiro–Wilk test. Differences between mean values were tested using Student's *t*-test or the Mann–Whitney test if the data were not normally distributed. The relationship between categorical variables was analyzed with a Chi² test. Statistical tests were performed with the statistical package, R version 3.3.3 (R Foundation, Vienna, Austria). A *P*-value ≤ 0.05 was considered as statistically significant.

3. Results

In the retrospective cohort, 83 patients (55%) underwent soft tissue procedures; 18 patients (35%) did so in the prospective cohort. These two groups were comparable in terms of age, sex, sports level, dominant side involvement, glenoid bone damage detected on imaging; however the breakdown of clinical forms defined for the symposium differed between groups (Table 1). The procedures performed in each cohort are shown on Figs. 1 and 2. Resorbable suture anchors were used in most cases – 3 on average. Postoperatively, immobilization in neutral rotation was used in 75 patients (74%) for an average of 5 weeks with rehabilitation starting after the 3rd week.

The mean follow-up in the retrospective cohort was 4.8 ± 2.6 years and 29 patients (35%) were considered failures: 7 cases of recurrent dislocation, 12 of recurrent subluxation and 10 of constant pain. The Walch–Duplay score was 75.9 ± 26.7 and the modified Rowe score was 80.3 ± 23.6 at the most recent follow-up. The VAS, SSV and Constant scores had also improved (Table 2). Sixty-five patients agreed to be re-operated, while 80% of patients were very satisfied (*n* = 44) or satisfied (*n* = 22) (Fig. 3). Seventy-six patients (92%) returned to work after an average of 5.5 months. Fifty-two patients (63%) resumed their sports participation and 16

Table 1
Preoperative characteristics of patients in the retrospective and prospective cohorts.

Cohort description	Retrospective (<i>n</i> = 83)	Prospective (<i>n</i> = 18)
Age (years ± SD)	28.9 ± 9.2	28.3 ± 10.6
Sex (male ratio)	59 (71%)	16 (89%)
Dominant side involved	54 (65%)	8 (44%)
Athletes	62 (75%)	11 (61%)
Competitive	20 (24%)	4 (22%)
Defined injury event	62 (75%)	17 (94%)
Involuntary	40 (48%)	14 (78%)
Voluntary	3 (4%)	0
Voluntary to involuntary	10 (12%)	2 (11%)
Painful	20 (24%)	2 (11%)
Unclassified	10 (12%)	0
Bone damage on CT scan (glenoid/humeral side)	28 (34%)/16 (19%)	6 (33%)/6 (33%)

Capsulolabral procedures (retrospective cohort)

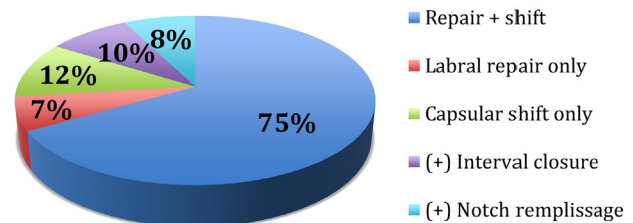


Fig. 1. Types of procedures performed to treat posterior shoulder instability in the retrospective cohort.

Capsulolabral procedures (prospective cohort)

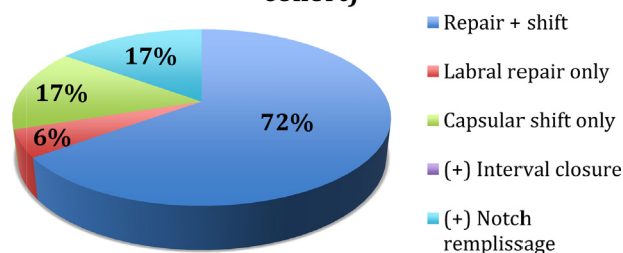


Fig. 2. Types of procedures performed to treat posterior shoulder instability in the prospective cohort.

Table 2

Non-specific outcome scores in the retrospective cohort.

Non-specific scores	Preoperative ^a	Postoperative ^a
Pain (VAS)/10	5.6 ± 2.4 (34)	2.4 ± 1.8 (68)
SSV/100	50.9 ± 21.6 (33)	84.2 ± 19.1 (71)
Overall Constant score	73.2 (42)	85.2 (76)
Pain	6.6	12.3
Function	13.4	17.4
Mobility	36.9	37.3
Strength	15.6	18.1

VAS: Visual Analog Scale; SSV: Subjective Shoulder Value.

^a Mean ± SD (n counts).

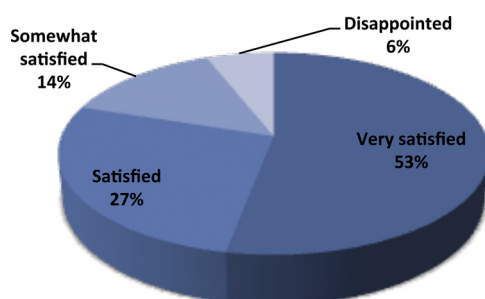


Fig. 3. Patient satisfaction in the entire cohort.

patients (80%) were at their pre-injury level after an average of 7.6 months.

The highest outcome scores were in the involuntary instability group (Table 3). There were no significant differences in the surgical technique used; however, isolated procedures were more common in the subset of patients considered as failures. No significant correlation was found in the subset of patients considered as failures (Fig. 4).

Table 3

Outcomes based on the clinical presentation (except voluntary group).

	Involuntary (n = 40)	Painful (n = 20)	Voluntary to involuntary (n = 10)	Unclassified (n = 10)
Overall Constant score	88.7	84.8	90.7	63.7
Pain	13.2	11.7	12.2	9.9
Mobility	38.5	37.2	39.3	30.8
Function	18.4	17.5	18.2	12.6
Pain (VAS)/10	1.0	2.2	3.3	2.5
SSV/100	87.0	82.5	87.1	69.4

VAS: Visual Analog Scale; SSV: Subjective Shoulder Value; n: number of patients in each group.

The mean follow-up in the prospective cohort was 1.1 ± 0.3 years; the outcomes were similar to those found in the retrospective cohort. Four patients (22%) were considered as failures: one case of recurrent subluxation and three of constant pain. The Walch–Duplay score improved by 43.5 ± 27.4 points and the modified Rowe score by 55.9 ± 27.6 points. Pain on the VAS was reduced by 2.4 points; the SSV improved by 27 points and the Constant score by 16.7 points (Table 4). Given the small cohort, no statistical analysis was performed.

No complications related to the hardware were found in either group. We did not come across more postoperative stiffness in patients who underwent rotator interval closure or notch remplissage. There were no neurological complications in the eight patients (six in retrospective cohort and two in prospective cohort) who underwent an open procedure.

4. Discussion

The shoulder specific and non-specific outcome scores were good after capsulolabral reconstruction for posterior shoulder instability; however, the failure rate was high. The rates of return to work (92%) and resumption of competitive sports (80%) were high. We did not find any significant difference in the outcome based on the various surgical techniques used, nor the various clinical presentations.

Analysis of the failure cases revealed this subset of patients was older than the non-failures cases (31.8 years versus 27.4 years). The breakdown of patients into various clinical forms also differed, with the failure cases having fewer patients from the involuntary group and more from the unclassified group [patients which did not fit in one of the four groups defined for this study] (Fig. 4). Our study confirmed that combined reconstruction with capsular shift procedures resulted in less failures than isolated capsular shift as suggested by Bradley et al. [13]. However, these differences were not statistically significant, likely due to the small

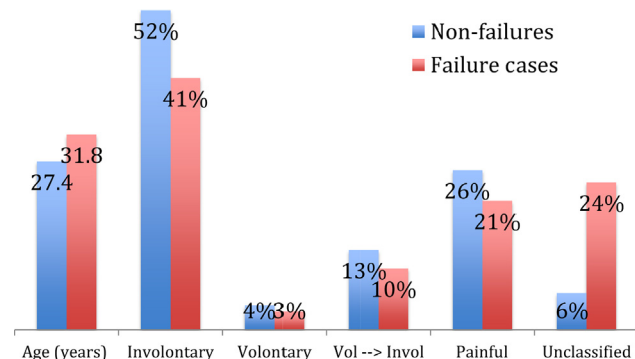


Fig. 4. Breakdown of clinical forms and age of the patients defined as failed cases versus non-failures.

Table 4

Outcomes in the prospective cohort.

Non-specific scores	Preoperative ^a	Postoperative ^a
Pain (VAS)/10	4.47 ± 2.7	2.39 ± 3.5
SSV/100	59.7 ± 18.4	87.1 ± 18.5
Overall Constant score	70.4 ± 18.4	87.1 ± 16.7
Pain	8.1	12.7
Function	11.8	17.3
Mobility	34.7	37.3
Strength	15.8	19.8
Walch–Duplay score/100	40.89 ± 21.8	85.3 ± 19.1
Modified Rowe score/100	33.5 ± 20.4	90 ± 18.3

VAS: Visual Analog Scale; SSV: Subjective Shoulder Value.

^a Mean ± SD.

number of patients in these subgroups. The small number of patients in the cohorts makes it impossible to identify risk factors for failure, no matter which surgical technique was used, clinical presentation or associated factors (bone damage, age, competitive sports).

The 2015 review of literature published by DeLong et al. [3] suggested better outcomes for arthroscopic techniques than open procedures during posterior shoulder stabilization. We did not specifically evaluate this point in our study as only eight patients underwent an open procedure. Their meta-analysis found a recurrence rate of 8.1% for all techniques combined with persistent pain in 12.3% of patients. The failure rate in our study, which took into account recurrence of the subluxation or dislocation along with constant pain, was higher than in large, recently published prospective studies [13,18]. This higher rate can be attributed to the broad definition of failure in our study (all patients who had recurrent dislocation, subluxation or constant pain) compared to other studies in which failure is defined relative to specific outcome scores, independently of the recurrence of subluxation or pain [3,7,13,14].

In our large retrospective cohort, the high failure rate (35%) must be placed in the context of the high patient satisfaction rate (80%) and the high portion of patients returning to work (92%) and resuming their sports (80% for competitive athletes). This is likely due to the difference in patients' expectations and the strict failure criterion used in our study. If failure had been defined as the recurrence of instability or pain in patients who were not satisfied or did not improve, the overall failure rate would be reduced from 31.7% to 13.4% with all treatments combined.

In the prospective study, the findings were similar but the failure rate lower. The primary reason for failure was the development of postoperative pain; there were few recurrences of the instability. The small number of patients included and the shorter follow-up did not allow us to extensively analyze these findings. In the patients with chronic instability, persistent pain outside instability episodes was—in some cases—related to cartilage damage that could not be addressed surgically.

Despite the bone damage over the posterior glenoid found in 33% of patients (Table 1), this subset of patients did not experience more failures following surgical treatment of soft tissues. Nevertheless, the extent of bone damage was not quantified. Bone damage is likely the best indication for a bone block procedure. Up to now, no study has looked at the extent of bone loss as an indication for bone block procedures in posterior instability [19]. A prospective study comparing these two techniques based on the extent of bone damage would allow us to better define the indications.

The small number of patients who underwent rotator interval closure and notch remplissage in combination with the capsule procedures did not allow us to identify risk factors specific to these techniques. Nevertheless, the outcomes were not superior nor did more complications occur when these procedures were performed. Postoperative stiffening reported in some studies after interval closure [20] was less for arthroscopic procedures than open ones because of supero-inferior closure instead of medio-lateral, which can explain our observations. To determine the impact of these associated procedures, a larger study is needed that takes into account the preoperative lesions and compares these various procedures in a prospective, randomized manner.

5. Conclusion

Treatment of posterior shoulder instability by capsulolabral reconstruction leads to good clinical outcomes; however, the failure rate was high based on our stringent criteria. The indication is most appropriate in young athletes with a clinical involuntary instability. The presence of small bone lesions on the glenoid side is not a contraindication to this type of treatment. The surgical procedure must combine capsular shifting with labral repair and potentially interval closure or notch remplissage.

Disclosure of interest

The authors declare that they have no competing interest.

References

- [1] Kowalsky MS, Levine WN. Traumatic posterior glenohumeral dislocation: classification, pathoanatomy, diagnosis, and treatment. *Orthop Clin North Am* 2008;39:519–33 [viii].
- [2] Provencher MT, LeClere LE, King S, et al. Posterior instability of the shoulder: diagnosis and management. *Am J Sports Med* 2011;39:874–86.
- [3] DeLong JM, Jiang K, Bradley JP. Posterior instability of the shoulder: a systematic review and meta-analysis of clinical outcomes. *Am J Sports Med* 2015;43:1805–17.
- [4] Robinson CM, Seah M, Akhtar MA. The epidemiology, risk of recurrence, and functional outcome after an acute traumatic posterior dislocation of the shoulder. *J Bone Joint Surg Am* 2011;93:1605–13.
- [5] Bottoni CR, Franks BR, Moore JH, DeBerardino TM, Taylor DC, Arciero RA. Operative stabilization of posterior shoulder instability. *Am J Sports Med* 2005;33:996–1002.
- [6] Kim SH, Ha KI, Park JH, et al. Arthroscopic posterior labral repair and capsular shift for traumatic unidirectional recurrent posterior subluxation of the shoulder. *J Bone Joint Surg Am* 2003;85-A:1479–87.
- [7] Savoie 3rd FH, Holt MS, Field LD, Ramsey JR. Arthroscopic management of posterior instability: evolution of technique and results. *Arthroscopy* 2008;24:389–96.
- [8] Williams 3rd RJ, Strickland S, Cohen M, Altchek DW, Warren RF. Arthroscopic repair for traumatic posterior shoulder instability. *Am J Sports Med* 2003;31:203–9.
- [9] Bigliani LU, Pollock RG, McIlveen SJ, Endrizzi DP, Flatow EL. Shift of the posteroinferior aspect of the capsule for recurrent posterior glenohumeral instability. *J Bone Joint Surg Am* 1995;77:1011–20.
- [10] Wolf BR, Strickland S, Williams RJ, Allen AA, Altchek DW, Warren RF. Open posterior stabilization for recurrent posterior glenohumeral instability. *J Shoulder Elbow Surg* 2005;14:157–64.
- [11] Leivadiotou D, Ahrens P. Arthroscopic treatment of posterior shoulder instability: a systematic review. *Arthroscopy* 2015;31:555–60.
- [12] Hawkins RJ, McCormack RG. Posterior shoulder instability. *Orthopedics* 1988;11:101–7.
- [13] Bradley JP, McClincy MP, Arner JW, Tejwani SG. Arthroscopic capsulolabral reconstruction for posterior instability of the shoulder: a prospective study of 200 shoulders. *Am J Sports Med* 2013;41:2005–14.
- [14] Provencher MT, Bell SJ, Menzel KA, Mologne TS. Arthroscopic treatment of posterior shoulder instability: results in 33 patients. *Am J Sports Med* 2005;33:1463–71.
- [15] Bradley JP, Baker 3rd CL, Kline AJ, Armfield DR, Chhabra A. Arthroscopic capsulolabral reconstruction for posterior instability of the shoulder: a prospective study of 100 shoulders. *Am J Sports Med* 2006;34:1061–71.
- [16] Khiami F, Sariali E, Rosenheim M, Hardy P. Anterior shoulder instability arthroscopic treatment outcomes measures: the WOSI correlates with the Walch–Duplay score. *Orthop Traumatol Surg Res* 2012;98:48–53.
- [17] Rowe CR. Instabilities of the glenohumeral joint. *Bull Hospital Jt Dis* 1978;39:180–6.
- [18] Radkowski CA, Chhabra A, Baker 3rd CL, Tejwani SG, Bradley JP. Arthroscopic capsulolabral repair for posterior shoulder instability in throwing athletes compared with nonthrowing athletes. *Am J Sports Med* 2008;36:693–9.
- [19] Longo UG, Rizzello G, Locher J, et al. Bone loss in patients with posterior glenohumeral instability: a systematic review. *Knee Surg Sports Traumatol Arthrosc* 2016;24:612–7.
- [20] Frank RM, Golijanan P, Gross DJ, Provencher MT. The arthroscopic rotator interval closure: why, when, and how? *Oper Tech Sports Med* 2014;22:48–57.