



Rhipicephalus (Boophilus) microplus (Arachnida: Ixodidae) larvae infestation of human eyelids. A rare case

Navpreet Kaur, Pawan Prasher, Khushhal Kumar, Sakshi Dhingra

► To cite this version:

Navpreet Kaur, Pawan Prasher, Khushhal Kumar, Sakshi Dhingra. Rhipicephalus (Boophilus) microplus (Arachnida: Ixodidae) larvae infestation of human eyelids. A rare case. *Acarologia*, 2019, 59 (1), pp.21-25. 10.24349/acarologia/20194309 . hal-01981481

HAL Id: hal-01981481

<https://hal.science/hal-01981481>


Submitted on 15 Jan 2019

HAL is a multi-disciplinary open access archive for the deposit and dissemination of scientific research documents, whether they are published or not. The documents may come from teaching and research institutions in France or abroad, or from public or private research centers.

L'archive ouverte pluridisciplinaire **HAL**, est destinée au dépôt et à la diffusion de documents scientifiques de niveau recherche, publiés ou non, émanant des établissements d'enseignement et de recherche français ou étrangers, des laboratoires publics ou privés.



Distributed under a Creative Commons Attribution 4.0 International License



Acarologia

A quarterly journal of acarology, since 1959
Publishing on all aspects of the Acari

All information:



<http://www1.montpellier.inra.fr/CBGP/acarologia/>
acarologia@supagro.inra.fr



**Acarologia is proudly non-profit,
with no page charges and free open access**

Please help us maintain this system by
encouraging your institutes to subscribe to the print version of the journal
and by sending us your high quality research on the Acari.

Subscriptions: Year 2019 (Volume 59): 450 €

<http://www1.montpellier.inra.fr/CBGP/acarologia/subscribe.php>

Previous volumes (2010-2017): 250 € / year (4 issues)

Acarologia, CBGP, CS 30016, 34988 MONTFERRIER-sur-LEZ Cedex, France

The digitalization of Acarologia papers prior to 2000 was supported by Agropolis Fondation under the reference ID 1500-024 through the « Investissements d'avenir » programme (Labex Agro: ANR-10-LABX-0001-01)



Acarologia is under **free license** and distributed under the terms of the Creative Commons-BY-NC-ND which permits unrestricted non-commercial use, distribution, and reproduction in any medium, provided the original author and source are credited.

Rhipicephalus (Boophilus) microplus (Arachnida: Ixodidae) larvae infestation of human eyelids. A rare case

Navpreet Kaur^a, Pawan Prasher^b, Khushhal Kumar^a, Sakshi Dhingra^a

^a Department of Zoology and Environmental Sciences, Punjabi University, Patiala, Punjab, India.

^b Department of Ophthalmology, Sri Guru Ram Das Institute of Medical Sciences and Research, Amritsar, Punjab, India.

Short note

ABSTRACT

An 82-year-old female patient with painful, watery, and itchy eyes was admitted for examination at the Sri Guru Ramdas Institute of Medical Sciences and Research. During the examination, a number of tick larvae were found attached to the patient's upper and lower eyelid margins. The ticks were manually removed and the patient was treated with topical ciprofloxacin eye ointment. Microscopic studies revealed that all specimens belonged to a single species *Rhipicephalus (Boophilus) microplus* Canestrini (Acari: Ixodidae) which parasitizes livestock. Although other cases of ocular infestations have been reported, this is the first in North India involving *R. (B.) microplus*. It is speculated that the patient's occupation, surrounding conditions and living propensities made her susceptible to contamination by ticks.

Keywords eyelid; tick; *Rhipicephalus (Boophilus) microplus*

Introduction

Ticks are hematophagous ectoparasites that infest amphibians, birds, mammals, and reptiles (Black and Piesman, 1994). Ticks rank second only after the mosquitoes in transmitting human infectious diseases worldwide (de la Fuente *et al.*, 2008).

Ocular infestations by ticks are unusual in humans, but cases have been reported in different areas of the world (e.g., Mentz *et al.*, 2016; Uzun *et al.*, 2016 and Lin *et al.*, 2016). Presented herein, is a case of ocular infestation by *R. (B.) microplus* larvae on the eyelids of an elderly female patient, a condition which has not been previously reported from North India.

Rhipicephalus (Boophilus) microplus is a single-host tick belonging to the family Ixodidae. Out of 106 reported tick species from India, *R. (B.) microplus* is considered the most important tick economically because of its impacts on livestock production (Ghosh *et al.*, 2007). As a vector of babesiosis (caused by the protozoan parasites *Babesia bovis* and *B. bigemina*) and anaplasmosis (caused by *Anaplasma marginale*) *R. microplus* adversely affects cattle health in tropical and subtropical areas of the world (Connell, 1974 and Oliveira-Sequeira *et al.*, 2005). The life cycle of *R. (B.) microplus* includes four developmental stages: egg, larva, nymph and adult. The newly hatched larvae crawl upon plants or grass to access the host. Larvae usually seek soft skin like inside flanks, thighs and forelegs for attachment (Estrada-Pena *et al.*, 2006). On a typical host, the rest of the life cycle continues, using the same host individual for all subsequent blood meals; only the engorged female will leave the host to lay her eggs on the ground.

Received 01 July 2018
Accepted 21 December 2018
Published 15 January 2019

Corresponding author
Sakshi Dhingra: sakshi_rs@pbi.ac.in

Academic editor
Karen McCoy

DOI
10.24349/acarologia/20194309

© Copyright
Kaur N. *et al.*

Distributed under
Creative Commons CC-BY 4.0

OPEN  ACCESS

How to cite this article Kaur N. *et al.* (2019), *Rhipicephalus (Boophilus) microplus* (Arachnida: Ixodidae) larvae infestation of human eyelids. A rare case. *Acarologia* 59(1): 21-25; DOI 10.24349/acarologia/20194309

Case Report

An 82-year-old female with itchy, red, and watery eyes was admitted to the Sri Guru Ramdas Institute of Medical Sciences and Research, Amritsar, Punjab. Slit lamp examination revealed that a large number of ticks adhered to the upper and lower eyelid margins of both eyes (Fig. 1). All ticks were manually removed with blunt forceps and preserved in 70% alcohol. After removal of the ticks, attachment sites were cleaned thoroughly with antiseptic solution (povidone-iodine solution). Ciprofloxacin 0.3% ointment was prescribed to be applied to the affected area twice daily for a week. On examination, the patient revealed that she was engaged in dairy farming and had close contact with domestic livestock. To find out the source of infestation, we visited patient's home with our co-fellows and observed that her livestock were heavily infested with the tick *R. (B.) microplus*. Despite of being aware about the infestation of their livestock, the patient's family had taken no action to control the ticks. They were advised to treat the animals with acaricides to avoid further infestations.

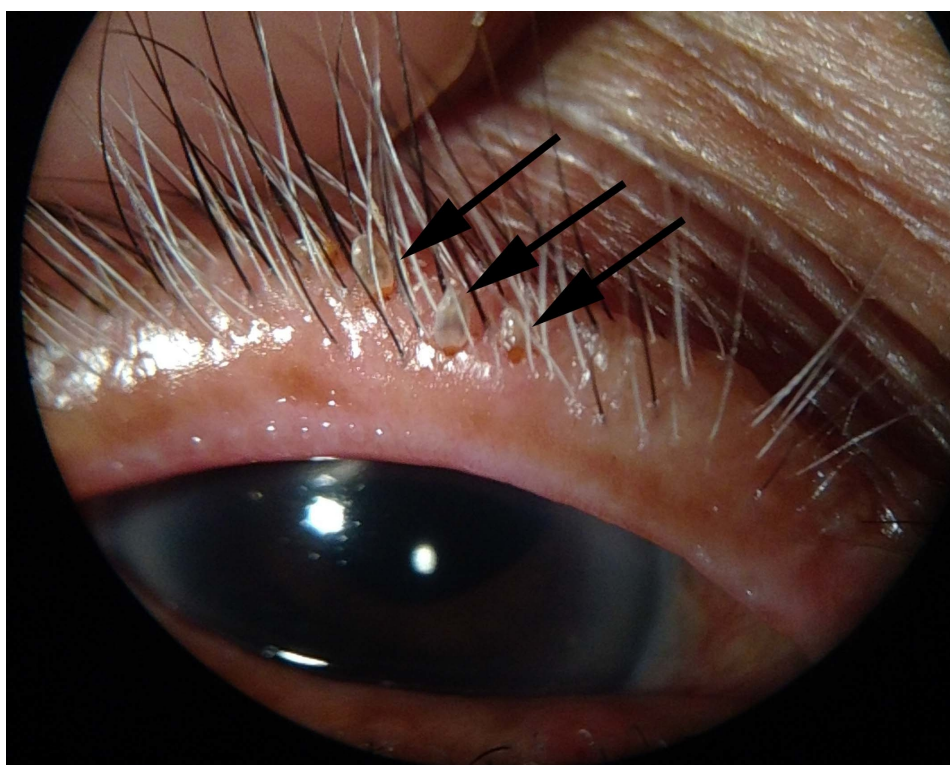

Figure 1 Arrows showing the larvae of *Rhipicephalus (B.) microplus* attached to the upper eyelid of the right eye.

For identification, specimens were submitted to the Acarology laboratory of the Department of Zoology and Environmental Sciences, Punjabi University Patiala, Punjab (India). After clearing the specimens in 60% lactic acid, permanent slides were prepared using Hoyer's medium. Photographs of the slides were taken in the Sophisticated Instrumentation Centre at Punjabi University Patiala, Punjab (India). The species identity of each specimen was determined based on morphology, following the descriptions and keys given by Walker and colleagues (Walker *et al.*, 2003). All the specimens were identified as larvae of *Rhipicephalus (Boophilus) microplus* (Fig. 2).



Figure 2 Larvae of *R. (B.) microplus*.

Discussion

Eyelid infestation with hematophagous ticks is a rare condition. Ticks infest humans in the absence of their natural host and/or when in close proximity to the natural hosts. Other cases of human eye infestation by *Ixodes ricinus* in the U.K. (McLeod, 1986; Bowes *et al.*, 2015) and by larvae of *Amblyomma americanum* in the U.S.A. (Bode *et al.*, 2006; Holak *et al.*, 2006) have been reported. In Turkey, Keklikci and co-workers reported *Ixodes ricinus* on the upper eyelid margin of a three-year-old girl and advised removing such ticks as soon as possible via mechanical procedures to prevent disease transmission (Keklikci *et al.*, 2009). Sakalar *et al.* reported a four-year-old girl with cellulitis due to infestation by nymphal forms of *Ixodes* sp. (Sakalar *et al.*, 2010). Celebi and Orkun presented a case report of tick infestation on the lower eyelid of a 71-year-old male with a nymph of *Dermacentor marginatus* (Celebi and Orkun, 2016).

A few instances of human eye infestation with ticks have been reported from India. In 1977, a case of *Rhipicephalus* sp. pervasion on the lower eyelid of a 22-year-old man was reported from Karela, India (Ittyerah and Fernandez, 1977). In the Chennai hospital, a 20-year-old male was admitted with painful swelling of the left lower eyelid that had been slowly progressing for 5 days. He was found to be infested with the tick *Rhipicephalus sanguineus* (Kumaran, 2015). Ticks belonging to genera *Haemaphysalis* were also reported infesting the lower eyelid of a male from Uttarakhand who had cattle and was sleeping at ground the night before the infestation (Kumar and Chhangte, 2015).

Severe disease associated with human tick infestations have been reported from India (Vasudevan and Chatterjee, 2013 and Celik *et al.*, 2013) including those transmitted by *R. (B.) microplus* such as babesiosis, and anaplasmosis (Ghosh and Nagar, 2014). To reduce the probability of transmission, ticks should be removed as soon as possible from patients; studies have shown that the risk of disease transmission increases after 24 hours of attachment and

is even higher after 48 hours (Gammons and Salam, 2002). For tick removal, chemical and mechanical methods have been suggested, but mechanical removal is considered as the most safe, quick, and effective method.

In the current case, larvae of *R. (B.) microplus* were found attached to the eyelids of the patient. The patient lived in close proximity to dairy cattle and other domestic animals increasing her potential for tick infestation. Clean surroundings, controlling infestation levels on animals, good personal hygiene, and avoiding prolonged direct contact with domestic animals can reduce the risk of tick infestation.

Acknowledgments

We are very grateful to Sophisticated Instrumentation Centre, Punjabi University Patiala, Punjab, for providing photography lab facilities and our co-fellow Dolly Bhagra for collaborating during the field visits. Heartly thanks to Dr. Karen McCoy for the improvement of the article.

References

- Black W.-C.-T., Piesman J. 1994. Phylogeny of hard- and soft-tick taxa (Acari: ixodida) based on mitochondrial 16S rDNA sequences. *Proc. Natl. Acad. Sci.* 91:10034–10038. doi:10.1073/pnas.91.21.10034
- Bode D., Speicher P., Harlan H. 2006. A seed tick infestation of the conjunctiva: *Amblyomma americanum* larva. *Ann. Ophthalmol.* 19(2): 63-64.
- Bowes O.-M.-B., Legg G., Haines R., Vardy S.-J. 2015. Tick infestation of the upper eyelid. *Can. J. Ophthalmol.* 50: 39-40. doi:10.1016/j.jcjo.2014.12.015
- Celebi A.-L.-C., Orkun O. 2016. A rare case of tick infestation of the eyelid: case report and literature review. *Rev. Bras. Ophthalmol.* 75(2): 144-146. doi:10.5935/0034-7280.20160030
- Celik E., Turkoglu B.-E., Boz A.-A.-E., Algoz G. 2013. Conjunctival attachment of a tick: Case report. *Semin. Ophthalmol.* 29(4): 186-188. doi:10.3109/08820538.2013.807847
- Connell M.-L. 1974. Transmission of *Anaplasma marginale* by the cattle tick *Boophilus microplus*. *J. Agric. Anim. Sci.* 31(3): 185-193.
- de la Fuente J., Estrada-Pe-a A., Venzal J.-M., Kocan K.-M., Sonenshine D.-E. 2008. Overview: Ticks as vectors of pathogens that cause disease in humans and animals. *Front Biosci.* 13: 6938–6946. doi:10.2741/3200
- Estrada-Pena A., Bouattour A., Camicas J.-L., Guglielmone A., Horak I., Jongejan F., Latif A., Pegram R., Walker A.-R. 2006. The known distribution and ecological preferences of the tick subgenus *Boophilus* (Acari: Ixodidae) in Africa and Latin America. *Exp. Appl. Acarol.* 38: 219-235. doi:10.1007/s10493-006-0003-5
- Gammons, M., Salam G. 2002. Tick removal. *Am. Fam. Physician* 66(4): 643-645.
- Ghosh S., Nagar G. 2014. Problem of ticks and tick-borne diseases in India with special emphasis on progress in tick control research: A review. *J. Vector Borne Dis.* 51: 259–270.
- Ghosh, S., Bansal, G. -C., Seitzer, U. and Ahmed, J. -S. 2007. Status of tick distribution in Bangladesh, India and Pakistan. *Parasitol. Res.* 2: 207-216. doi:10.1007/s00436-007-0684-7
- Holak H., Holak N., Huzarska M., Holak S. 2006. Tick inoculation in an eyelid region: report on five cases with one complication of the orbital myositis associated with Lyme borreliosis. *Klin. Oczna.* 108(4-6): 220-224.
- Ittyerah T.-P., Fernandez S.-T. 1977. *Rhipicephalus* on the eyelid margin. *Indian J. Ophthalmol.* 1977; 25: 4142.
- Keklikci U., Unlü K., Cakmak A., Akdeniz S., Akpolat N. 2009. Tick infestation of the eyelid: a case report in a child. *Turk. J. Pediatr.* 51: 172-173.
- Kumar P., Chhangte L. 2015. Tick Infestation of Lower Eyelid: A rare occurrence. *IOSR J. Den. Med. Sci.* 14(8): 68-70.
- Kumaran M. 2015. *Rhipicephalus sanguineus* Laterallis on Eyelid. *D.J.O.* 25: 286-287.
- Lin Y.-H., Yeung L., Sun C.-C., Ku W.-C., Yang J.-W. 2016. Contact dermatitis on the lower eyelid related to tick infestation: A case report in Taiwan. *Taiwan J. Ophthalmol.* 6(4): 201-203. doi:10.1016/j.tjo.2016.05.008
- McLeod, B.-K. 1986. Sheep tick in the eyelid. *Br. J. Ophthalmol.* 70: 75-76. doi:10.1136/bjo.70.1.75
- Mentz M.-B., Trombka M., Silva G.-L., Silva C.-E. 2016. *Rhipicephalus sanguineus* (Acari: Ixodidae) biting a human being in portoalegre city, Rio Grande do Sul, Brazil. *Rev. Inst. Med. Trop. Sao. Paulo.* 58: 35. doi:10.1590/s1678-9946201658035
- Oliveira-Sequeira T.-C.-G., Oliveira M.-C.-S., Araujo J.-P., Amarante A.-F.-T. 2005. PCR based detection of *Babesia bovis* and *Babesia bigemina* in their natural host *Boophilus microplus* and cattle. *Int. J. Parasitol.* 35(1): 105-111. doi:10.1016/j.jipara.2004.09.002
- Sakalar Y.-B., Arserim N.-B., Keklikci U., Balsak S., Alakus M.-F., Unlu K. 2010. Kene Enfestasyonuna Baoly Preseptal Selulit. *Turk. J. Ophthalmol.* 40(5): 307-9.

- Uzun A., Gok M., İşcanlı M. D. 2016. Tick Infestation of Eyelid: Two case reports. Turk. J. Ophthalmol. 46(5): 248-250. doi:[10.4274/tjo.43660](https://doi.org/10.4274/tjo.43660)
- Vasudevan B., Chatterjee M. 2013. Lyme borreliosis and skin. Indian J. Dermatol. 58: 167 174. doi:[10.4103/0019-5154.110822](https://doi.org/10.4103/0019-5154.110822)
- Walker A.-R., Bouattour A., Camicas J.-L., Estrada-Pe-a A., Horak I. G., Latif A.-A., Pegram R.-G., and Preston P.-M. 2003. Ticks of Domestic Animals in Africa: A guide to identification of species. U.K. Bioscience reports Edinburgh Scotland. pp.277.