



HAL
open science

A non steroidal anti inflammatory drug (ketoprofen) does not delay β -TCP bone graft healing

Hervé Oscar Nyangoga, Eric Aguado, Eric Goyenvalle, Michel Félix Baslé,
Daniel Chappard

► **To cite this version:**

Hervé Oscar Nyangoga, Eric Aguado, Eric Goyenvalle, Michel Félix Baslé, Daniel Chappard. A non steroidal anti inflammatory drug (ketoprofen) does not delay β -TCP bone graft healing. *Acta Biomaterialia*, 2010, 6 (8), pp.3310-3317. 10.1016/j.actbio.2010.01.042 . hal-00840064

HAL Id: hal-00840064

<https://hal.science/hal-00840064>

Submitted on 1 Jul 2013

HAL is a multi-disciplinary open access archive for the deposit and dissemination of scientific research documents, whether they are published or not. The documents may come from teaching and research institutions in France or abroad, or from public or private research centers.

L'archive ouverte pluridisciplinaire **HAL**, est destinée au dépôt et à la diffusion de documents scientifiques de niveau recherche, publiés ou non, émanant des établissements d'enseignement et de recherche français ou étrangers, des laboratoires publics ou privés.

A non steroidal anti inflammatory drug (ketoprofen) does not delay β -TCP bone graft healing

Herve Nyangoga^a, Eric Aguado^{a, b}, Eric Goyenvalle^{a, b}, Michel Felix Baslé^a, Daniel Chappard^{a*}

^a INSERM, U922 – LHEA, Faculté de Médecine, 49045 ANGERS Cedex -FRANCE.

^b BBTCEX, Ecole Nationale Vétérinaire de Nantes, 44307 NANTES Cedex-FRANCE

e-mail: daniel.chappard@univ-angers.fr

doi: 10.1016/j.actbio.2010.01.042

Key words: β -TCP, bone healing; non-steroidal anti inflammatory drugs; bone graft; microCT

Abstract

β -TCP is a suitable biomaterial in oral and maxillofacial surgery since it can induce a rapid proliferation of woven bone. Granules, prepared by the polyurethane foam method, were implanted in critical size defects performed in the femoral condyles of New Zealand rabbits. Animals were studied after 8 and 28 days. Ketoprofen (a non steroidal anti inflammatory drug - NSAID) was given during 8 and 28 days to evaluate its effects on the healing of the graft. Before euthanasia, the rabbits received an intravenous injection of fluorescent microbeads. Bones were analyzed by microcomputed tomography. β -TCP granules induced metaplastic bone trabeculae as early as 8 days post-surgery. At 28 days, the amount of bone was increased and the biomaterial volume decreased due to simultaneous macrophagic resorption. The amount of macrophages labeled with microbeads was less in the grafted area than in the vicinal intact marrow spaces. Ketoprofen had no effect on the amount of bone formed and on the number of labeled macrophages. The influence of small doses of NSAID, given in a short duration period, did not present deleterious effects on bone graft healing.

Introduction

Synthetic calcium/phosphate biomaterials are nowadays currently used for the repair of bone defects. They offer considerable safety versus bone allografts or xenogenic bone. An ideal biomaterial must be able to induce a localized osteogenesis which constitutes the first step of the ossification process by a modeling process; it should be followed by a phase of resorption of the material. Tri calcium phosphate (β -TCP) has been recognized as a suitable ceramic material with bioactive properties since several decades [1,2,3]. β -TCP is used in maxillo and orofacial surgery, in dental implantology but has received little attention in orthopedics because of its

friability that preclude its use in weight bearing areas [4,5,6,7]. Mixtures of β -TCP and hydroxyapatite (HA) have been proposed (and are often referred as BCP - biphasic calcium phosphate)[8]. However, BCP properties, depend on an optimum balance between the HA phase (more stable) and the β -TCP phase (more soluble) and controversies exist concerning as to how long HA persist in the body and reports from the orthopedic literature indicate that β -TCP provide better results [9]. However, β -TCP is known to be an excellent promotor of osteoblastic formation and is readily resorbed by macrophages and osteoclasts. Direct bone matrix anchorage has been shown with collagen fibers deposited in the micropores [10]. Resorption of β -TCP by giant cells has been recently reported in a rabbit model with cells having or not a ruffled border (a characteristic of osteoclasts) [10].

Nonsteroidal anti inflammatory drugs have analgesic, antipyretic and anti inflammatory properties. NSAIDs reduce fever, pain and they prevent inflammation. The ectopic new bone formation in the soft tissues around the hip joint can also be prevented by using NSAIDs [11]. A 14-day post-surgery treatment with ibuprofen has been shown to reduce the occurrence of chronic pain and disability with a low risk of adverse effects. NSAID treatments are simple and cheap to administer. However, a number of studies have reported adverse effects of NSAIDs which can delay the consolidation of fractures or the incorporation of the biomaterials because they interfere with the bone remodeling, in particular by their action on the production of prostaglandins [12,13,14,15,16]. In addition, these drugs have been found to impair tendon healing in preclinical studies [17].

The aims of this work was to study the effect of a NSAID, ketoprofen, on the osteoconduction induced by a graft of β -TCP in a model of bone defect in the rabbit. Fluorescent microbeads of a biocompatible polymer (poly 2(hydroxyethyl methacrylate)-pHEMA) were injected at the time of euthanasia to appreciate the macrophagic function in the grafted area.

Material and methods

All chemical reagents were obtained from Sigma-Aldrich Chemical (Illkirsh, France). Commercial 2-hydroxyethyl methacrylate (HEMA) contains impurities, due to the fabrication process. The polymerization inhibitor 4-methoxyphenol (added by the manufacturer before shipping, at a concentration of 350 ppm) also needs to be removed. HEMA was purified and distilled under reduced pressure. Benzoyl peroxide (BPO) was recrystallized in methanol two times before use to remove impurities.

Preparation of pHEMA microbeads

Microbeads of pHEMA labeled with Nile red were prepared according to our previously reported protocol with minor modifications [18,19]. Briefly, microbeads were prepared by an emulsion precipitation method by using the monomer HEMA (2-hydroxyethyl methacrylate). All reagents were obtained from Sigma-Aldrich (Saint-Quentin Fallavier, France). Benzoyl peroxide (2% w/v) a polymerization initiator, was dissolved in the monomer under magnetic stirring. The Nile red (2 mg), a fluorescent dye, was added. The diluent solution was made of a toluene/butanol mixture (40/60 v/v) in which a steric stabilizer, ethyl cellulose (3%, v/v) was dissolved. The diluent was heated at 40°C in a polymerization reactor; thereafter the monomer was added drop by drop in the reactor. Homogenization was done with an incorporated agitator. The mixture was maintained under nitrogen atmosphere for 15 minutes and temperature was increased until 75°C. After 2 hours, the EGDMA (ethylene glycol dimethacrylate) (3% v/v), a cross-linking agent, was added. Thereafter, the reaction was let to complete during 6 hours to

obtain microbeads. After this period, microbeads were washed with Histo-Clear II® (a mixture of aliphatic hydrocarbon and distilled essential oils – food grade, reduced citrus odor, National Diagnostics, Atlanta, Georgia, USA) to eliminate monomer residues and to preserve fluorescence. They were centrifuged three times and washed in Histo-Clear II®, before dispersion and drying for 24 hours. At the end, a powder containing millions of dried microbeads was obtained.

Animals and surgical procedure

Eighteen New Zealand rabbits (approximate weight 3.5 kg) were used in this study. They were acclimated during 8 days to the local vivarium conditions and received synthetic food and water ad libitum. Animals were randomly divided into two groups (Fig. 1):

- 6 animals were operated at D₀ and sacrificed 8 days after surgery to study the early remodeling phase around β -TCP granules. They constituted the D8 group; among them, 3 received ketoprofen (Ketofen® 1%, Merial S.A.S., Lyon, France) (daily dose: 2 mg / kg subcutaneously) and constituted the D8K⁺ group, the remaining 3 rabbits did not received the NSAID (D8K⁻ group).
- 12 rabbits were operated at D₀ and sacrificed 28 days after surgery to study the late remodeling phase around β -TCP granules. They constituted the D28 group; among them, 3 received ketoprofen all along the study (daily dose: 2 mg / kg subcutaneously) and constituted the D28K⁺ group; 4 received ketoprofen during a limited period of one week post-surgery (D28K^L); the remaining 5 rabbits did not received the NSAID (D28K⁻ group).

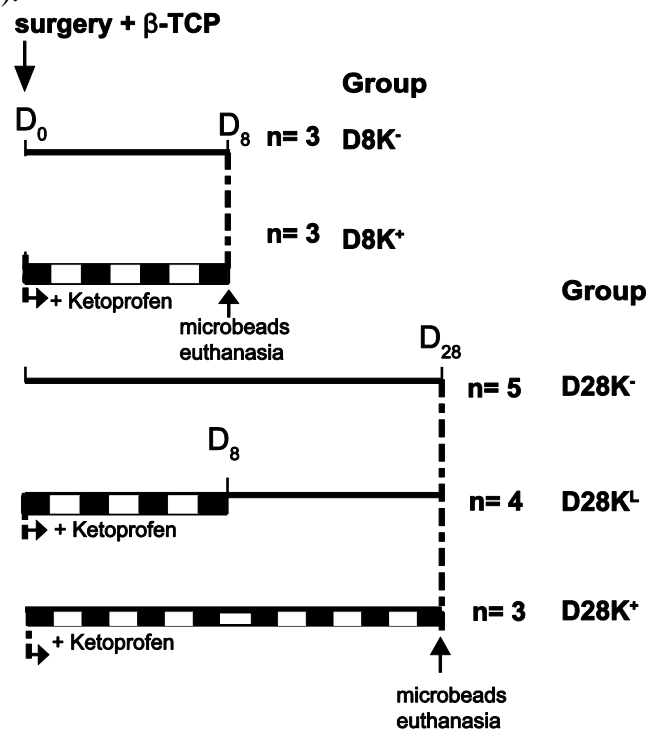


Fig. 1 Flow chart of the present study. Periods of ketoprofen administration appear with a checkboard pattern.

Bilateral femoral implantations were performed under aseptic conditions and general anesthesia with medetomidine (Domitor®, Pfizer, Paris, France) and ketamin (Imalgène 1000®, MERIAL SAS, Villeurbanne, France). After skin incisions and lateral arthrotomy access via the knee joint,

a cylindrical defect (4 mm diameter and 6 mm long) was created at the distal femoral end and then filled with 1000-2000 μm β -TCP granules (Kasios, Launaguet-France) (Fig. 2). The granules were placed after the cavity had been flushed with sterile saline to remove debris. Incision was closed by different layers with resorbable sutures. Implantation control was done to be ensuring that the β -TCP granules have been implanted in the right position.




Fig. 2 Granules of β -TCP examined by scanning electron microscopy. A) Note the general shape of the granules with a grossly polygonal aspect and the small internal voids created by the disappearance of the polyurethane foam during the sintering phase of the biomaterial preparation (arrow). B) surface morphology of a β -TCP granule showing the pavement-like structure at higher magnification.

The animals were sacrificed 8 and 28 days after implantation. 4 hours before euthanasia, animals were injected in the ear marginal vein with a saline solution containing 3×10^8 microbeads per ml. The 4 hour period was chosen according to a previous study showing that pHEMA microbeads were rapidly internalized by endothelial cells and by *in vivo* experiments indicating that microbeads were secondarily found in the cytoplasm of macrophages [19]. Then euthanasia was done by injecting an intracardiac overdose of sodium pentobarbital (Dolethal, Vetoquinol, France). The lower femoral extremities were immediately dissected from the animal and fixed in 10% formalin. The care and use of these laboratory animals was in compliance with French law on animal experimentation.

Radiographs of the implanted bones were performed *ex vivo* using a Faxitron X-ray system (MX20, Edimex, Angers, France) with a 5 x 5 cm CCD camera. The accelerating voltage was fixed at 35 kV with a 15 s exposure time.

β -TCP granules

β -TCP granules were prepared by the polyurethane foam technology and provided by Kasios (Launaguet, France) [20]. Granules were 1000-2000 μm in diameter and their morphology was verified by scanning electron microscopy. The sequence of operations for preparing sintered calcium-phosphate materials is based on previous works presented in the literature [21]. Briefly, a slurry containing 25g of β -TCP was prepared with distilled water and used to substantially impregnate a block of polyurethane foam under vacuum. This ensured that the ceramic coated the polyurethane walls to produce a replica of the reticulated foam material, the ceramic parts of the biomaterial being centered by the polymer. The blocks of polyurethane impregnated with the slurry were then dried in an oven and then heated in a furnace oven at 800°C; this led to a complete burn of the organic polyurethane foam. The 3D scaffold of β -TCP were then sintered at a temperature >1200°C and granules were obtained by crushing the blocks in an alumina mortar.

Microtomography analysis (MicroCT)

The Skyscan 1076 X-ray computed microtomograph (Skyscan - Kontich, Belgium) was used in the cone beam acquisition mode. The system is composed of a sealed microfocus X-ray tube, air cooled with a spot size less than 8 μm and a CCD camera. Images were obtained at 80kV and 120 μA with a 1 mm aluminum filter, the pixel size was 18.96 μm and a 0.45° rotation angle at each step. Specimens were placed in a plastic test tube filled with the fixative. Tubes were fixed with plasticine on the brass stub of the microCT. 2D section Images were stored in the bmp format with indexed grey levels ranging from 0 (black) to 255 (white) that served to reconstruct 3D models with programs provided by the manufacturer (softwares used: ANT release # 2.4.3 and Ct-An 1.8). The ANT program allows reconstruction of 3D models from the stack of 2D sections after interactive segmentation. The histomorphometric parameters were recorded in compliance with the recommendation of the American Society for Bone and Mineral Research (ASBMR) Histomorphometry Nomenclature Committee [22]. The Ct-An software provided the following parameters after determination of the volume of interest (VOI) comprising the whole grafted area. VOI was obtained by tracing polygons on 2D images o separated by approximately 50 μm ; an algorithm interpolated the polygons with the intermediate sections.

- The bone volume (BV/TV, in %) is the ratio of the volume of bone present (BV) to the total VOI (i.e., TV).
- The Material volume (MatV/TV, in %) is the ratio of the volume of the remaining amount of β -TCP presen to the VOI. MatV/TV could be determined because the radio-opacity of β -TCP was higher than bone and allowed a selective thresholding.
- Trabecular thickness (in μm) was measured separately in the newly-formed trabeculae in the grafted bone ($\text{Tb}_g.\text{Th}$) and in the mature trabeculae of the epiphysis, at distance from the graft ($\text{Tb}_e.\text{Th}$).

Histology after undecalcified processing

Bones were embedded undecalcified in poly methylmethacrylate. The infiltration of bone samples and the embedding process were performed in a cold environment as previously described [23]. Sections 7 μm in thickness were cut dry using a microtome with carbide tungsten knives (Microtome Leica Polycut S). Staining was performed with a modification of the toluidine blue borax method. Unstained sections were use to quantify the amount of fluorescent microbeads by fluorescence microscopy (Olympus BX51 Microscope, excitation cube U-MWIG2) both in the zone grafted and in the marrow spaces of the epiphysis. A microscopic

eyepiece comprising a rectangular reticle of known surface was used to count the number of macrophagic cells containing clusters of microbeads on several contiguous fields. The number of microbeads by surface unit was calculated separately in the grafted area ($Mb.N/T.Ar_g$) and at distance in the ungrafted cancellous spaces of the epiphysis ($Mb.N/T.Ar_e$).

Statistical analysis:

Statistical analysis was performed using Systat[®] statistical software release 11.0 (Systat Software, San Jose, CA). Differences among groups were searched with the Kruskal-Wallis One-Way Analysis of Variance and differences between groups by Mann-Whitney's U test when the ANOVA revealed a significant difference. Differences were considered as significant when $p < 0.05$. Results were expressed as mean standard deviation.

Results

Granules morphology

At scanning electron microscopy, the material appeared composed of large round cavities. Internal voids (created by the disappearance of the polymer foam) were observed (Fig. 2A). The surface of the material appeared composed of a regular paving composed of geometric tiles with a rounded top (Fig. 2B).

X-ray analysis

On X-ray images, the biomaterial was hardly evidenced due to its higher radio-opacity (Fig. 3). However, the osteoconduction could not be evidenced because the epiphyseal trabeculae overimposed onto the material granules and the newly formed bone.

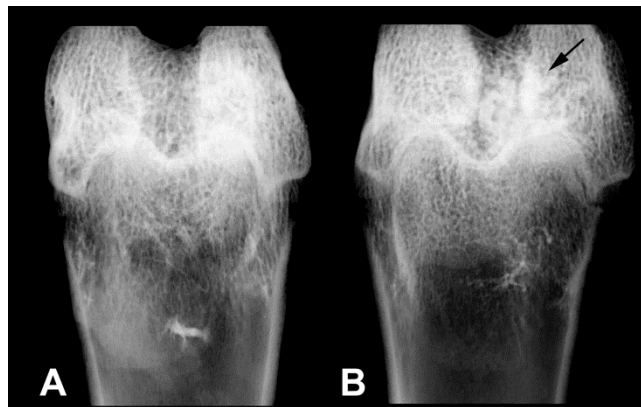


Fig. 3 X-ray image of a control rabbit femur (A) and a femur grafted with β -TCP granules and examined at 8 days.

MicroCT

At 8 days, the porous granules of β -TCP were easily observable on 2D images. They appeared more radio opaque than bone itself. rabbits having received or not ketoprofen, The granules have retained their polygonal shape with sharp angles and the internal porosity due to the manufacture process was easily recognizable, indicating that resorption of the biomaterial had remained limited at this stage. On the other hand, osteogenesis has yet begun and appeared in the form of

thin trabeculae advancing in direction of the grafted zone in a centripetal way starting from the vicinal trabeculae of the epiphysis (Fig. 4A & B and Fig. 5A). These trabeculae were less radiopaque than the mature bone trabeculae on the 2D sections and their microarchitecture evoked metaplastic bone (woven bone).

At 28 days, many β -TCP granules presented a coarsely round shape and a reduction of their size was obvious. A larger number of thin metaplastic trabeculae were observed around the grafted area and extending between the biomaterial granules (Fig. 4C, D, E and Fig. 5B). β -TCP appeared partially reabsorbed and the centripetal osteogenesis progressed inside the grafted area.

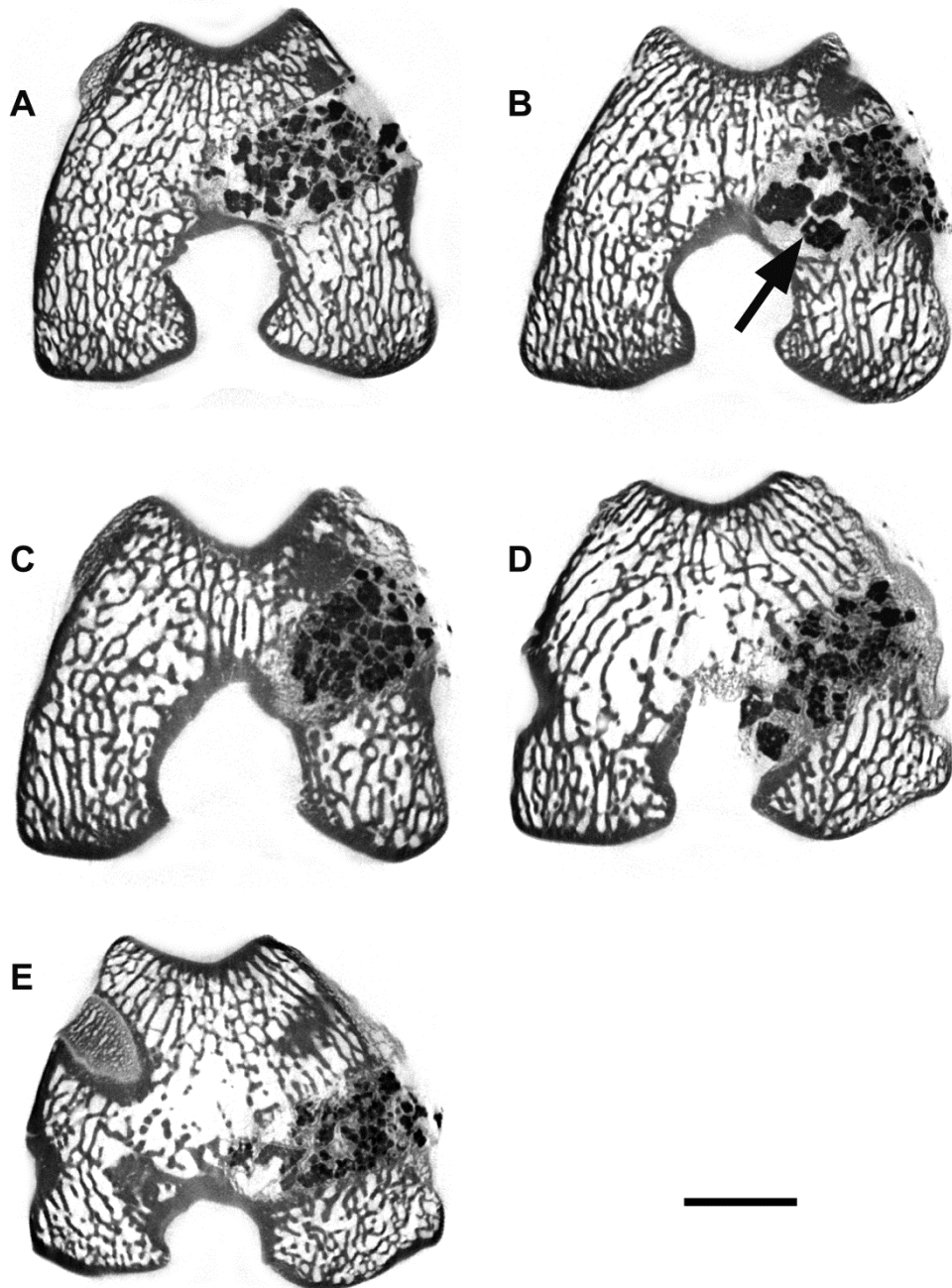


Fig. 4 MicroCT analysis of the femoral condyles of rabbits implanted with β -TCP (2D sections). A and B: at 8 days; C, D, E at 28 days post-surgery. A and C: without ketoprofen; B and E with ketoprofen received during the whole course of the study; D; with ketoprofen received during 8 days post surgery. B) the arrows point to the internal void of a β -TCP granule. The bar stands for 4 mm.

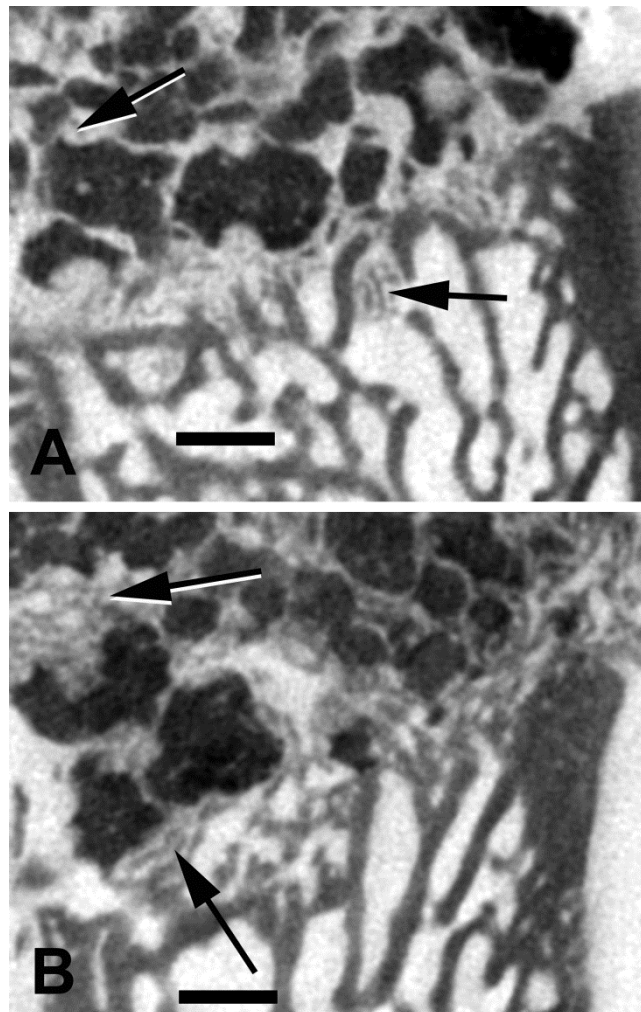
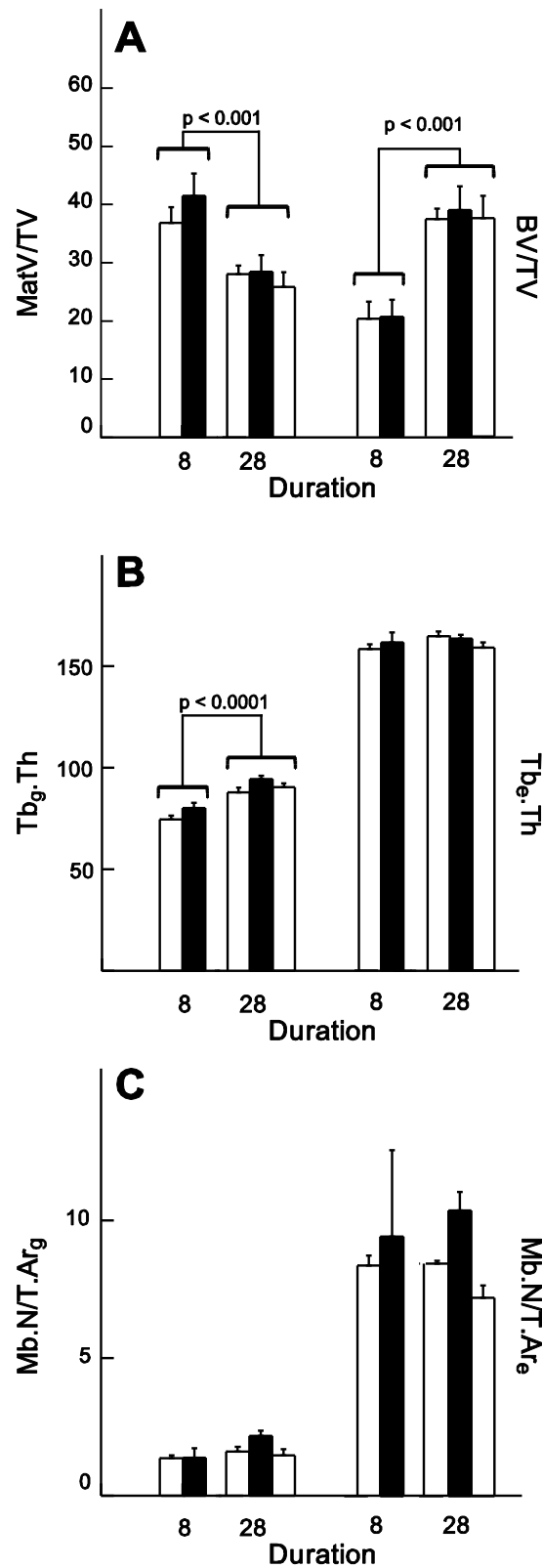


Fig. 5 MicroCT analysis of the femoral condyles of rabbits implanted with β -TCP (2D sections at an higher magnification). A) at 8 days post-surgery, note the beginning of osteoconduction from the margins of the hole with thin metaplastic bone trabeculae. B) at 28 days post-surgery, the gross shape of the β -TCP granules has changed; the amount of metaplastic bone is considerably enhanced with larger metaplastic trabeculae (arrows) extending from the margins of the hole to the very center of the grafted area. The bar stands for 100 μ m.

No gross morphological differences could be observed between the groups of animals treated or not with ketoprofen (neither at 8 nor at 28 days).

The volume of newly formed bone in the zone of graft (BV/TV) did not significantly differ for between the groups D8K⁻ and D8K⁺ at 8 days, however, BV/TV increased significantly at D28 ($p < 0.001$) (Fig. 6A). MatV/TV did not differ among groups at D8 or D28 but was significantly reduced in all groups at D28 ($p < 0.001$). No significant difference between the 3 groups was observed at 28 days. The thickness of the trabeculae in the epiphysis (Tb_e.Th) was similar in all groups and did not vary between D8 and D28. Tb_g.Th was significantly lower in the metaplastic trabeculae compared to Tb_e.Th ($p < 0.0001$). A significant difference was observed for Tb_g.Th between the groups at 8 days and at 28 days ($p < 0.0001$) with a moderate increased thickness of approximately 13 μ m (Fig. 6B). Ketoprofen had no influence on the trabecular thickness of the metaplastic bone trabeculae at any time.

**Fig. 6**

Histomorphometric results obtained in rabbit grafted with β -TCP. Ketoprofen therapy: without (white), with continuous treatment (black) and receiving only one week post surgery (dashed lines).

Histology

Histological analysis revealed the presence of a non inflammatory loose connective tissue (made of mesenchymal cells) between the β -TCP granules and the newly formed bone trabeculae. The mesenchymal reaction was always highly vascular with numerous sinusoid capillaries. The center of the connective tissue areas always contained numerous macrophages filled with minute particles of β -TCP (Fig. 7). Some giant cells and osteoclast-like cells were also found at the surface of the biomaterial. Histological findings confirmed microCT data with metaplastic bone extending from the surrounding areas to the grafted β -TCP granules. At D28, the amount of metaplastic bone was important and trabeculae were found directly apposed onto the surface of the biomaterial. A number of pseudo-epithelial alignments of osteoblasts were observed at surface of newly-formed bone on the biomaterial granules.

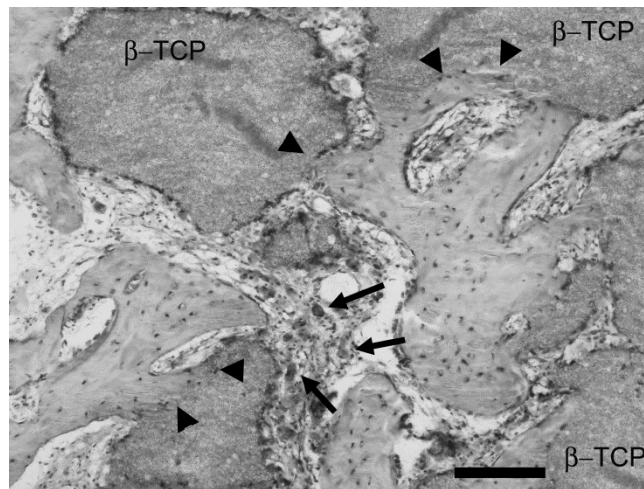


Fig. 7 Histological section of the grafted area showing the β -TCP granules and the development of the mesenchymal reaction around the granules. Note the presence of macrophages filled with phagocytosed particles of the biomaterial (arrows). Note the bone bonding onto the β -TCP granules (arrowheads). The bar stands for 100 μ m. Toluidine blue staining.

The number of microbeads was evaluated in fluorescence microscopy in the zone grafted and compared with the remainder of marrow spaces of the epiphysis. A very limited number of microbeads was observed in marrow spaces of the grafted zone in which the mesenchymal area had developed between the grains (Fig. 6C). On the contrary, Mb.N/T.Ar_e was significantly higher, meaning that a large number of macrophagic cells appeared loaded with microbeads in the remainder of marrow spaces of the epiphysis (Fig. 8A & B).

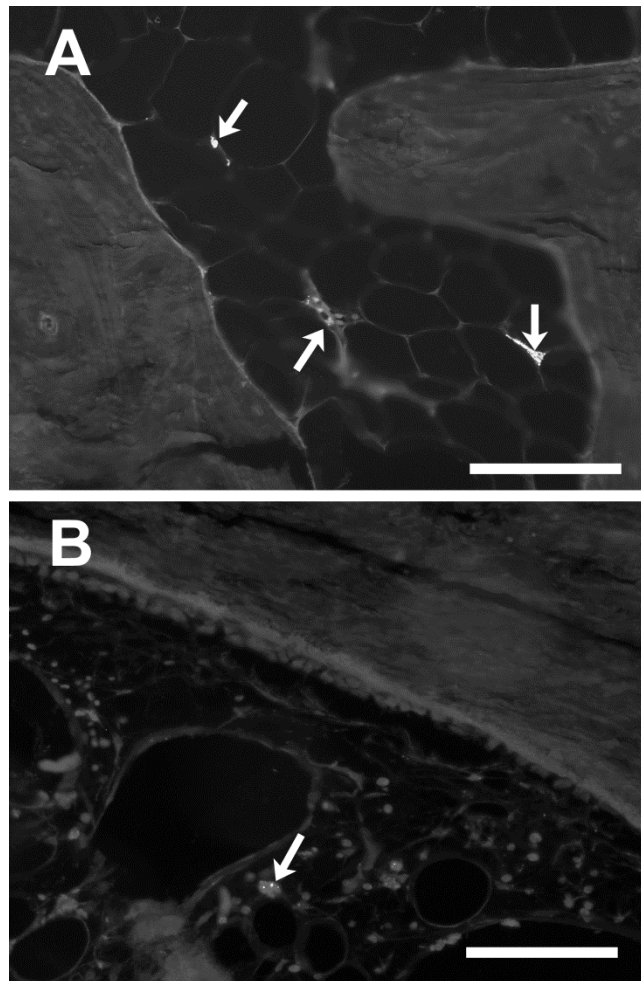


Fig. 8 Fluorescence microscopy showing the pHEMA microbeads in the macrophages in marrow spaces at distance in the epiphysis (arrows) (A) and in the grafted area (arrows), the bar stands for 100 μ m. (B).

There were no difference for Mb.N/T.Ar_g according to the treatment by ketoprofen between the groups D8K⁻ and D8K⁺ at 8 days, nor with between the 3 groups at 28 days. No significant difference between the groups was observed for Mb.N/T.Ar_e whatever the duration of the study or the treatment.

Discussion

The use of porous calcium phosphate granules is recognized as filler or packing biomaterials in an osseous environment. Therefore, β -TCP used as a bone substitute in oral and maxillofacial surgery for alveolar socket filling after tooth extraction [24] or maxillary sinus floor elevation [25,26]. Although autologous bone is considered as the best material for such techniques, the increased morbidity (due to the harvesting of bone in another surgical location in the same patient) has led to develop other techniques. In addition, the use of synthetic biomaterials such as β -TCP is reported to be associated with a lower (or the same) risk of failure or complications [5]. In orthopaedic surgery, β -TCP granules are seldom used because of the friability of the material in weight-bearing areas although interesting results have been presented [27,28]. In the present study, commercially available β -TCP granules were use as a bone filler in a critical size defect

performed in the femoral condyle of the rabbit. Ketoprofen was used as an anti inflammatory drug to evaluate its effects on the bone in growth induced by β -TCP in this model.

NSAID and cyclo-oxygenase-2 (COX-2) inhibitors are commonly prescribed after orthopedic or maxillofacial surgery, and their anti inflammatory effects are due to their impairment of COX-1 and/or COX-2. These compounds have not the deleterious effects on bone cells and remodeling of glucocorticoids (see review by Bouvard [29]). However, long term use of NSAID has been repeatedly reported to interfere with bone remodeling and to delay bone healing [30,31,32]. Similar findings have been found in a number of animal studied [33,34]. However more recent findings have shown that, when given for shorter periods of times, (e.g. 2 to 6 weeks in New Zealand rabbits), the deleterious effects are less pronounced [35,36] allowing the patients to benefit from the analgesic and anti inflammatory properties of these compounds. Because the clinical scenario after orthopaedic (or oral and maxillofacial surgery), is presently more to prescribe a low dose of NSAID for a short duration, this study was designed with two regimens (8 days and 28 days) during the healing phase of a bone graft. None of the two regimens had influence on the amount of bone deposited or on the microarchitectural quality of the trabeculae formed by osteoconduction induced by β -TCP. Ketoprofen is a NSAID with an antiCOX-1 and antiCOX-2 activity, however, little is known concerning the level of the two isoforms of COX at the grafted site of a bone biomaterial or in a fracture callus [37]. In this study, the onset of metaplastic bone formation occurred rapidly since the first trabeculae could be identified as early as 8 days post-grafting. Similar findings have been reported in the rat grafted with β -TCP in which thin trabeculae were observed as early as 7 days post-surgery [38]. Ketoprofen did not delay the centripetal bone formation starting from the vicinal trabeculae at the periphery of the implantation area. It should also be reminded that selective COX-2 inhibitors have been found to have serious cardio-vascular side effects and some (rofecoxib, Vioxx[®]) have now been withdrawn over safety concerns [39,40].

Microbeads are a useful tool to study the angiogenesis in tumors and could be used to deliver locally high amounts of angiogenic inhibitors [41]. pHEMA is a well recognized polymer in biomedicine [42] and microbeads can be readily prepared. In this study, microbeads containing Nile red were prepared as a fluorescent tracer for endothelial cells and macrophages. Microbeads can be rapidly trapped by endothelial cells (particularly in the case of rapid angiogenesis) and phagocytosed by macrophages in the stroma of the tissues [19]. This as been recognized as the Enhanced Permeability Retention effect [41,43,44]. Methacrylate-based polymers can be easily prepared in the form of micro or nanobeads usable as carriers [45]. In addition, we previously showed that macrophages can phagocytose and internalize the pHEMA hydrogel [46]. In this study, the rabbits were euthanized 4 hours after injection of the microbeads, a time sufficient to allow their internalization by macrophages at the periphery of the sinusoid capillaries of the bone marrow. The number of fluorescently-labeled macrophages was much lower in the grafted zone than in the ungrafted cancellous areas of the epiphysis. Although the number of macrophages has been recognized to be increased in the mesenchymal reaction around β -TCP granules [47,48,49], this finding may appear be intriguing. However, macrophages in the grafted area were filled with β -TCP particles and they are probably less susceptible to internalize a new type of material. NSAIDs can reduce the macrophagic function in inflammatory diseases [50]. Here again, the amount of labeled macrophages did not differ in the ketoprofen-treated groups from the control ones, either in the short or the longer periods of analysis.

β -TCP granules, implanted in a critical size defect in the rabbit, induced the rapid and extensive proliferation of bone trabeculae, starting from the margins of the implantation area. Ketoprofen, given during 8 or 28 days had no effect on osteogenesis or on the uptake of fluorescent microbeads by activated macrophages in the grafted area. Although NSAIDs (given during a

long period of time) are known to delay fracture healing, their effect in short time treatment on a biomaterial graft healing appear insignificant.

Acknowledgments

This work was made possible by grants from INSERM and Contrat Région Pays de la Loire (Bioregos2 program). Authors thank Mrs. Laurence Lechat for secretarial assistance and Kasios ZI La Croix, 31140 Launaguët – France for providing the biomaterial.. They also thank Mrs Florence Pascaretti-Grizon for skilful assistance with the histological technique and Romain Mallet for help with Scanning Electron Microscopy. SEM analysis was done at SCIAM (Service Commun d'Imagerie et Analyses Microscopiques), Université d'Angers.

References

- [1] Daculsi G, Laboux O, Malard O, Weiss P. Current state of the art of biphasic calcium phosphate bioceramics. *J Mater Sci-Mater Med* 2003;14:195-200.
- [2] Driessen AA, Klein CP, de Groot K. Preparation and some properties of sintered beta-whitlockite. *Biomaterials* 1982;3:113-6.
- [3] Jarcho M. Calcium phosphate ceramics as hard tissue prosthetics. *Clin Orthop Relat Res* 1981;259-78.
- [4] Aunoble S, Clément D, Frayssinet P, Harmand MF, Le Huec JC. Biological performance of a new β -TCP/PLLA composite material for applications in spine surgery: In vitro and in vivo studies. *J Biomed Mater Res - Part A* 2006;78:416-22.
- [5] Horch HH, Sader R, Pautke C, Neff A, Deppe H, Kolk A. Synthetic, pure-phase beta-tricalcium phosphate ceramic granules (Cerasorb[®]) for bone regeneration in the reconstructive surgery of the jaws. *Int J Oral Maxillofac Surg* 2006;35:708-13.
- [6] Meyer C, Chatelain B, Benarroch M, Garnier JF, Ricbourg B, Camponovo T. Massive sinus-lift procedures with β -tricalcium phosphate: Long-term results. *Rev Stomatol Chirur Maxillo-Fac* 2009; 110 69-75.
- [7] Bornstein MM, Chappuis V, Von Arx T, Buser D. Performance of dental implants after staged sinus floor elevation procedures: 5-year results of a prospective study in partially edentulous patients. *Clin Oral Implants Res* 2008;19:1034-43.
- [8] Daculsi G, Layrolle P. Osteoinductive Properties of Micro Macroporous Biphasic Calcium Phosphate Bioceramics. *Key Engen Mater* 2004;254-256:1005-8.
- [9] Ogose A, Hotta T, Kawashima H, Kondo N, Gu W, Kamura T, Endo N. Comparison of hydroxyapatite and beta tricalcium phosphate as bone substitutes after excision of bone tumors. *J Biomed Mater Res- Part B* 2005;72:94-101.
- [10] Chazono M, Tanaka T, Kitasato S, Kikuchi T, Marumo K. Electron microscopic study on bone formation and bioresorption after implantation of beta-tricalcium phosphate in rabbit models. *J Orthop Sci* 2008;13:550-5.
- [11] Fransen M. Preventing chronic ectopic bone-related pain and disability after hip replacement surgery with perioperative ibuprofen. A multicenter, randomized, double-blind, placebo-controlled trial (HIPAID). *Control Clin Trials* 2004;25:223-33.
- [12] Beck A, Krischak G, Sorg T, Augat P, Farker K, Merkel U, Kinzl L, et al. Influence of diclofenac (group of nonsteroidal anti-inflammatory drugs) on fracture healing. *Arch Orthop Trauma Surg* 2003;123:327-32.

- [13] Endo K, Sairyō K, Komatsubara S, Sasa T, Egawa H, Ogawa T, Yonekura D, et al. Cyclooxygenase-2 inhibitor delays fracture healing in rats. *Acta Orthopaedica* 2005;76:470-4.
- [14] Giannoudis PV, MacDonald DA, Matthews SJ, Smith RM, Furlong AJ, De Boer P. Nonunion of the femoral diaphysis. *J Bone Joint Surg Br* 2000;82:655-8.
- [15] Giordano V, Giordano M, Knackfuss IG, Apfel MIR, Gomes RDC. Effect of tenoxicam on fracture healing in rat tibiae. *Injury* 2003;34:85-94.
- [16] Pountos I, Georgouli T, Blokhuis TJ, Pape HC, Giannoudis PV. Pharmacological agents and impairment of fracture healing: What is the evidence? *Injury* 2008;39:384-94.
- [17] Dimmen S, Engebretsen L, Nordsletten L, Madsen JE. Negative effects of parecoxib and indomethacin on tendon healing: an experimental study in rats. *Knee Surg Sports Traumatol Arthrosc* 2009;17:835-9.
- [18] Horak D, Karpisek M, Turkova J, Benes M. Hydrazide-functionalized poly(2-hydroxyethyl methacrylate) microspheres for immobilization of horseradish peroxidase. *Biotechnol Prog* 1999;15:208-15.
- [19] Nyangoga H, Zecheru T, Filmon R, Baslé MF, Cincu C, Chappard D. Synthesis and use of pHEMA microbeads with human EA.hy 926 endothelial cells. *J Biomed Mater Res-Part B* 2009;89:501-7.
- [20] Filmon R, Retailliau-Gaborit N, Brossard G, Grizon-Pascaretti F, Baslé MF, Chappard D. Preparation of β -TCP granular material by polyurethane foam technology. *Image Anal Stereol* 2009; 28:1-10.
- [21] Schwartzwalder K, Somers H, Somers AV. Method of making porous ceramics. 1963, US Patent:3 090 094
- [22] Parfitt AM, Drezner MK, Glorieux FG, Kanis JA, Malluche H, Meunier PJ, Ott SM, et al. Bone histomorphometry: standardization of nomenclature, symbols, and units. Report of the ASBMR Histomorphometry Nomenclature Committee. *J Bone Miner Res* 1987; 2:595-610.
- [23] Chappard D, Technical aspects: How do we best prepare bone samples for proper histological analysis?, In: Heymann D editors, "Bone cancer: progression and therapeutic approaches", London, Acad. Press. Elsevier Inc., 2009, pp 203-10.
- [24] Zerbo IR, Bronckers AL, de Lange GL, van Beek GJ, Burger EH. Histology of human alveolar bone regeneration with a porous tricalcium phosphate. A report of two cases. *Clin Oral Implants Res* 2001;12:379-84.
- [25] Zijdeveld SA, Zerbo IR, van den Bergh JP, Schulten EA, ten Bruggenkate CM. Maxillary sinus floor augmentation using a beta-tricalcium phosphate (Cerasorb) alone compared to autogenous bone grafts. *Int J Oral Maxillofac Implants* 2005;20:432-40.
- [26] Knabe C, Koch C, Rack A, Stiller M. Effect of beta-tricalcium phosphate particles with varying porosity on osteogenesis after sinus floor augmentation in humans. *Biomaterials* 2008;29:2249-58.
- [27] Galois L, Mainard D, Delagoutte JP. Beta-tricalcium phosphate ceramic as a bone substitute in orthopaedic surgery. *Int Orthop* 2002;26:109-15.
- [28] Muschik M, Ludwig R, Halbhubner S, Bursche K, Stoll T. Beta-tricalcium phosphate as a bone substitute for dorsal spinal fusion in adolescent idiopathic scoliosis: preliminary results of a prospective clinical study. *Eur Spine J* 2001;10:S178-84.
- [29] Bouvard B, Legrand E, Audran M, Chappard D. Glucocorticoid-induced osteoporosis: a review. *Clin Rev Bone Miner Metab* 2009;DOI: 10.1007/s12018-009-9051-9:1-12.
- [30] Gerstenfeld LC, Thiede M, Seibert K, Mielke C, Phippard D, Svagr B, Cullinane D, et al. Differential inhibition of fracture healing by non-selective and cyclooxygenase-2 selective non-steroidal anti-inflammatory drugs. *J Orthop Res* 2003;21:670-5.

- [31] Harder AT, An YH. The mechanisms of the inhibitory effects of nonsteroidal anti-inflammatory drugs on bone healing: a concise review. *J Clin Pharmacol* 2003;43:807-15.
- [32] Seidenberg AB, An YH. Is there an inhibitory effect of COX-2 inhibitors on bone healing? *Pharmacol Res* 2004;50:151-6.
- [33] Bo J, Sudmann E, Marton PF. Effect of indomethacin on fracture healing in rats. *Acta Orthop Scand* 1976;47:588-99.
- [34] Sudmann E, Bang G. Indomethacin-induced inhibition of haversian remodelling in rabbits. *Acta Orthop Scand* 1979;50:621-7.
- [35] Goodman SB, Ma T, Mitsunaga L, Miyanishi K, Genovese MC, Smith RL. Temporal effects of a COX-2-selective NSAID on bone ingrowth. *J Biomed Mater Res - Part A* 2005;72:279-87.
- [36] Karachalios T, Boursinos L, Poultsides L, Khaldi L, Malizos KN. The effects of the short-term administration of low therapeutic doses of anti-COX-2 agents on the healing of fractures. An experimental study in rabbits. *J Bone Joint Surg Br* 2007;89:1253-60.
- [37] Boursinos LA, Karachalios T, Poultsides L, Malizos KN. Do steroids, conventional non-steroidal anti-inflammatory drugs and selective Cox-2 inhibitors adversely affect fracture healing? *J Musculoskelet Neuronal Interact* 2009;9:44-52.
- [38] Kondo N, Ogoose A, Tokunaga K, Ito T, Arai K, Kudo N, Inoue H, et al. Bone formation and resorption of highly purified beta-tricalcium phosphate in the rat femoral condyle. *Biomaterials* 2005;26:5600-8.
- [39] Solomon DH, Schneeweiss S, Glynn RJ, Kiyota Y, Levin R, Mogun H, Avorn J. Relationship between Selective Cyclooxygenase-2 Inhibitors and Acute Myocardial Infarction in Older Adults. *Circulation* 2004;109:2068-73.
- [40] Jüni P, Nartey L, Reichenbach S, Sterchi R, Dieppe PA, Egger PM. Risk of cardiovascular events and rofecoxib: Cumulative meta-analysis. *Lancet* 2004;364:2021-9.
- [41] Maeda H, Fang J, Inutsuka T, Kitamoto Y. Vascular permeability enhancement in solid tumor: various factors, mechanisms involved and its implications. *Int Immunopharmacol* 2003;3:319-28.
- [42] Monthéard J, Kahovec J, Chappard D, Homopolymers and copolymers of 2-hydroxyethyl Methacrylate for biomedical applications., In: Arshady R editors, "Desk Reference of Functional Polymers; Syntheses and Applications ", Washington DC, American Chemical Society, 1997, pp 699-717.
- [43] Iyer AK, Khaled G, Fang J, Maeda H. Exploiting the enhanced permeability and retention effect for tumor targeting. *Drug Discov Today* 2006;11:812-8.
- [44] Maeda H, Wu J, Sawa T, Matsumura Y, Hori K. Tumor vascular permeability and the EPR effect in macromolecular therapeutics: a review. *J Control Release* 2000;65:271-84.
- [45] Zecheru T, Filmon R, Rusen E, Marculescu B, Zerroukhi A, Cincu C, Chappard D. Biomimetic potential of some methacrylate-based copolymers: a comparative study. *Biopolymers* 2009;91:966-73.
- [46] Mabileau G, Moreau MF, Filmon R, Baslé MF, Chappard D. Biodegradability of poly (2-hydroxyethyl methacrylate) in the presence of the J774.2 macrophage cell line. *Biomaterials* 2004;25:5155-62.
- [47] Nagahara K, Isogai M, Shibata K, Meenaghan MA. Osteogenesis of hydroxyapatite and tricalcium phosphate used as a bone substitute. *Int J Oral Maxillofac Implants* 1992;7:72-9.
- [48] Eggli PS, Muller W, Schenk RK. Porous hydroxyapatite and tricalcium phosphate cylinders with two different pore size ranges implanted in the cancellous bone of rabbits. A comparative histomorphometric and histologic study of bony ingrowth and implant substitution. *Clin Orthop Relat Res* 1988;127-38.

- [49] Kim Y-H, Jyoti A, Byun I-S, Oh I-H, Min Y-K, Yang H-M, Lee B-T, et al. Effects of macrophage on biodegradation of β -tricalcium phosphate bone graft substitute. *J Kor Ceram Soc* 2008;45:618-24.
- [50] Suzuki Y, Nishiyama T, Hasuda K, Fujishiro T, Niikura T, Hayashi S, Hashimoto S, et al. Effect of etidronate on COX-2 expression and PGE(2) production in macrophage-like RAW 264.7 cells stimulated by titanium particles. *J Orthop Sci* 2007;12:568-77.