

Non-Invasive Determination of Breslow Index

Amouroux Marine and Blondel Walter
Centre de Recherche en Automatique de Nancy (CRAN)
UMR 7039 CNRS – Nancy University,
2 avenue de la Forêt de Haye, 54516 Vandoeuvre-lès-Nancy cedex
France

1. Introduction

1.1 Current melanoma diagnosis

1.1.1 Histopathology is the current gold standard technique of melanoma diagnosis

Although histopathologic examination remains the gold standard for cancer diagnosis, melanoma has the potential to be diagnosed through noninvasive approaches because of its cutaneous location (Rigel, Russak et al. 2010). Whenever a suspicious skin lesion is removed a histological examination is warranted (Garbe, Peris et al. 2009). The histopathologic report should include the following information (Ruiter, Spatz et al. 2002):

- Diagnosis and clinicopathologic type; when there is uncertainty about malignancy it should be clearly stated in the report conclusion,
- Tumour thickness in mm (Breslow depth),
- Presence or absence of ulceration,
- Level of invasion (Clark level), especially for thin melanomas <1mm in thickness,
- Microsatellites (if present), and
- Lateral and deep excision margins.

Besides these absolutely necessary histologic features, additional informations can be provided, including:

- Number of mitoses per mm² (in hot spots). The mitotic activity can inform about the risk of relapse and, in some series, the probability of sentinel node positivity,
- Growth phase (horizontal or vertical),
- Presence or absence of established regression,
- Presence or absence of a dense tumour infiltrating lymphocytes (TIL) infiltrate,
- Lymphatic emboli, and
- Vascular or perineural involvement.

In some instances, when the histologic diagnosis is unclear, immunohistochemical stains may be helpful (i.e. S-100 protein, HMB45 and Melan-A for the confirmation of the melanocytic nature of the tumour, HMB45 as an additional feature of malignancy when there is an inverted positive gradient, MIB-1 as a proliferation marker). It is advised to use standardised pathology worksheets. An example of such a standardised pathology worksheet can be downloaded at www.melanomagroup.eu.

1.1.2 American Joint Committee on Cancer (AJCC) Tumor-Node-Metastasis (TNM) classification of melanomas

Tables 1 and 2 display most recent (2009) classification as well as clinical and pathological staging recommended by the American Joint Committee on Cancer (AJCC) (Balch, Gershenwald et al. 2009).

| Classification | Thickness (mm) | Ulceration Status/Mitoses |
|---|--|--|
| Tis | NA | NA |
| T1 | ≤ 1.00 | a: without ulceration and mitoses < 1/mm ² b: with ulceration or mitoses > 1/mm ² |
| T2 | 1.01-2.00 | a: without ulceration b: with ulceration |
| T3 | 2.01-4.00 | a: without ulceration b: with ulceration |
| T4 | > 4.00 | a: without ulceration b: with ulceration |
| | Number of metastatic nodes | Nodal metastatic burden |
| N0 | 0 | NA |
| N1 | 1 | a: micrometastasis b: macrometastasis |
| N2 | 2-3 | a: micrometastasis b: macrometastasis c: In transit metastases/staellites without metastatic nodes |
| N3 | 4 + metastatic nodes, or matted nodes, or in transit metastases/satellites with metastatic nodes | |
| | Site | Serum LDH |
| M0 | No distant metastases | NA |
| M1a | Distant skin, subcutaneous, or nodal metastases | Normal |
| M1b | Lung metastases | Normal |
| M1c | All other visceral metastases | Normal |
| | Any distant metastases | Elevated |
| Abbreviations: T, tumor; N, node; M, metastasis; is, in situ; NA, not applicable; LDH, lactate deshydrogenase. Micrometastases are diagnosed after sentinle lymph node biopsy Macrometastases are defined as clinically detectable nodal metastases confirmed patholoically | | |

Table 1. TNM staging categories of cutaneous melanoma

| | Clinical staging | | | | Pathologic staging | | | | |
|------|------------------|-------|--------|-------|--------------------|-------|-------|-----|----|
| | T | N | M | | T | N | M | | |
| 0 | Tis | N0 | M0 | 0 | Tis | N0 | M0 | | |
| IA | T1a | N0 | M0 | IA | T1a | N0 | M0 | | |
| IB | T1b | N0 | M0 | IB | T1b | N0 | M0 | | |
| | T2a | N0 | M0 | | T2a | N0 | M0 | | |
| IIA | T2b | N0 | M0 | IIA | T2b | N0 | M0 | | |
| | T3a | N0 | M0 | | T3a | N0 | M0 | | |
| IIB | T3b | N0 | M0 | IIB | T3b | N0 | M0 | | |
| | T4a | N0 | M0 | | T4a | N0 | M0 | | |
| IIC | T4b | N0 | M0 | IIC | T4b | N0 | M0 | | |
| | III | Any T | N > N0 | | M0 | IIIA | T1-4a | N1a | M0 |
| IIIB | | | | T1-4a | | N2a | M0 | | |
| | | | | | | T1-4b | N1a | M0 | |
| | | | | | | | | | |
| | | | | | | | | | |
| | | | | | | | | | |
| | | | | | | | | | |
| | | | | | | | | | |
| | | | | | | | | | |
| | | | | | | | | | |
| | | | | | | | | | |
| IV | | | | | | Any T | Any N | M1 | IV |

Clinical staging includes microstaging of the primary melanoma and clinical/radiologic evaluation for metastases. By convention, it should be used after complete excision of the primary melanoma with clinical assessment for regional and distant metastases. Pathologic staging includes microstaging of the primary melanoma and pathologic information about the regional lymph nodes after partial (IE, sentinel node biopsy) or complete lymphadenectomy. Pathologic stage 0 or stage IA patients are the exception; they do not require pathologic evaluation of their lymph nodes.

Table 2. Anatomic stage groupings for cutaneous melanoma

1.2 Breslow index

Among the aforementioned pathologic features to be determined in a histopathologic report of a melanoma diagnosis, tumour thickness also mentioned as Breslow index, is the basic criterion for staging a melanoma, once malignancy is confirmed.

1.2.1 Definition of Breslow index

By means of an ocular micrometer, the maximal thickness of the lesion is measured in several slides from the top of the granular cell layer to the deepest point of invasion. If the lesion is ulcerated, the ulcer base over the deepest point of invasion is used rather than the top of the granular cell layer (Breslow 1975). Such maximal thickness is called "Breslow index".

1.2.2 Breslow index plays several roles in melanoma management

As soon as in 1970, Alexander Breslow proposed tumour thickness as a valuable tool in prognosing patients' survival as well as in selecting patients for prophylactic lymph node dissection (Breslow 1970). Breslow index is also used for recommendations of melanoma excision margins (Lens, Nathan et al. 2007).

1.2.2.1 Breslow index as a prognostic factor

Melanoma prognosis is based on several clinical and histopathological criteria (Tichy, Ditrichova et al. 2007). As seen in Table 2, the most significant and independent one is Breslow index. In 1975, Breslow explains that a serious problem in using Clark's levels of invasion as a prognostic factor is the difficulty in differentiating between an advanced level II and a level III lesion as the difference is somewhat subjective unless instruction was given by Dr. Clark himself. By contrast, measurement of tumor thickness is objective, and good agreement among pathologists is to be expected (Breslow 1975). Last recommendations by the AJCC mention that for thinnest melanomas (i.e. Breslow index < 1 mm), the mitotic rate histologically defined as mitoses per mm² replaces Clark level for defining T1b stage melanomas compared to the 2002 edition of the AJCC melanoma staging system.

1.2.2.2 Breslow index as the determination factor of excision margins

The primary treatment of melanoma is surgical excision. An excisional biopsy is preferred, both to give the dermatopathologist/pathologist an optimal specimen and to allow evaluation of the excision margins for residual tumour. Incisional biopsies should not be performed when an excisional biopsy is technically possible. The definitive surgical excision should be performed with safety margins preferentially within 4–6 weeks after initial diagnosis. The recommendations mentioned in table 3 are consistent with the evidence that smaller excision margins are appropriate; the values given in table 3 are in concordance with the American and Australian recommendations. The current recommendations are based on both prospective, randomised studies and international consensus conferences. There are limited data to suggest that margin has an effect on loco-regional recurrence, but there are no data to support an impact of margin on survival (Garbe, Peris et al. 2009).

| Tumour thickness (Breslow index) | Excision margin (cm) |
|----------------------------------|----------------------|
| In situ | 0.5 |
| ≤ 2 mm | 1 |
| > 2 cm | 2 |

Table 3. Recommended excision margins of melanomas

1.2.2.3 Breslow index as the primary predictive factor of sentinel lymph node status

Sentinel Lymph Node Biopsy (SLNB) is a minimally invasive technique developed to identify patients with nodal metastases and who could be candidates for complete lymph node dissection (Johnson, Sondak et al. 2006). A positive SLNB has been shown to be the best predictor of recurrence and survival in patients with clinically node-negative cutaneous melanoma (Wagner, Ranieri et al. 2003). Patient mean charges for SLNB and wide excision alone respectively are \$12,193 and \$1,466 (Agnese, Abdessalam et al. 2003). In the Multicenter Selective Lymphadenectomy Trial, an overall complication rate of 10% after lymphatic mapping and sentinel lymph node biopsy was reported (46% wound infection) (Cascinelli, Bombardieri et al. 2006). Allergic reactions to the blue dye have also been rarely reported

(Daley, Norman et al. 2004). Thus selection of patients for SLNB is an area of debate. Breslow index is a validated, reproducible factor that is predictive of SLN status, and it currently is the primary criterion used to determine whether or not SLN biopsy is considered (Paek, Griffith et al. 2007). National Comprehensive Cancer Network recommendations are to perform SLNB on appropriate patients defined as patients with stage IA thin melanomas (1.0 mm or less) with adverse prognostic factors such as thickness over 0.75 mm, positive deep margins, lymphovascular invasion, or young patient age. Ranieri et al (Ranieri, Wagner et al. 2006) mention Breslow thickness, Clark level of invasion and mitotic index as statistically significant criteria in disease subset <1 mm in predicting the SLNB result. In the disease subset .75 to 1.0 mm thick, only mitotic index was predictive of the SLNB result.

2. Interest of non-invasive determination of Breslow index

The objective of this current chapter is to review the techniques whose potential to non-invasively determine Breslow index has been studied. Basic and technical principles of each technique will be mentioned as well as their accuracy in the determination of a factor whose importance in the clinical management of melanoma is so important as previously demonstrated. Currently Breslow index is measured by the anatomic-pathologist after incisional or excisional biopsy of the suspected lesion. So why non-invasive determination of Breslow index would be of utmost clinical value?

The accuracy of a biopsy depends on the expertise of the clinician. If a decision not to do a complete excision is made, partial biopsy specimens are usually taken from the most deeply pigmented, elevated, nodular, or other clinically suspect area. However, as a result of sampling error or a lack of correlation between the clinical and histological features, the portion biopsied may not be the most histologically representative portion of the lesion (Ng, Barzilai et al. 2003). Ng et al (Ng, Barzilai et al. 2003) found that in 95 of 108 initial shave or punch biopsies (88%), the physicians' clinical assessment of the melanoma for biopsy was accurate. A majority (84.8%) of the latter physicians were dermatologists with a median time of 11 years of post residency clinical experience. Khorshid et al found that general practitioners made a confident clinical diagnosis of melanoma 17% of the time and that the rate of incomplete excisions was significantly higher among general practitioners (Khorshid, Pinney et al. 1998).

Moreover SLNB can be affected by the surgical resection of the primary lesion. When the primary lesion is intact or excised with a narrow margin, the lymphatic vessels draining the lesion remain intact, making SLNB a highly accurate method of identifying the lymph node basins at risk and the lymph nodes most likely to harbor metastatic disease. Although SLNB and wide local excision (WLE) are usually performed during a single operation, some patients are referred for SLN identification after a WLE has been performed. There is concern that the patterns of afferent lymphatic flow from a primary tumour site in this setting may be altered as a result of a WLE's disruption of the lymphatic vessels. This disruption may negatively impact the ability to identify SLNs and/or render SLNB less accurate in reflecting the pathologic status of the draining lymph node basins in these patients, since the remaining drainage pathways identified may no longer represent the primary tumour's actual drainage. Theoretically, SLNB could misidentify the true SLNs, leaving patients at greater risk for lymph node basin failure and denying some patients the potential benefit of early therapeutic lymph node dissection and early adjuvant therapy (Gannon, Rousseau et al. 2006). Studies are controversial on whether or not prior WLE

impairs SLN status. Lesion location bias and rotational flap closure have been proposed as explanations to such controversies (McCready, Ghazarian et al. 2001; Gannon, Rousseau et al. 2006).

In conclusion to such clinical problems associated with invasive determination of Breslow index, we think that non-invasive determination of Breslow index would be a great advance in every day clinical management of melanoma. What techniques have been proposed to do so?

3. Non-invasive determination of Breslow index

Techniques for non-invasive Breslow determination use either mechanical or electromagnetic waves. A wave is the propagation of a perturbation inducing reversible variations of local physical properties. It transports energy but no matter. Ultrasounds and optical waves are used mainly because of their innocuousness.

In the next paragraphs, ultrasonography then several optical techniques will be developed. Basic physical principles of each type of wave interaction with skin will be described then accuracy of Breslow index determination by such techniques will be given. One paragraph will talk about techniques that have already given promising results in a clinical environment *in vivo*, namely ultrasonography and dermoscopy. A second paragraph will address Diffuse Reflectance Spectroscopy (DRS) that has been tested on phantoms mimicking melanoma. A third paragraph will talk about two techniques that have given preliminary results on potential Breslow index determination: the first one, infrared microimaging, performed on fixed and paraffin-embedded tissues (i.e. after excision of the tumour) and the second one, photoacoustic microscopy, performed *in vivo* on mice on which melanoma human cells were xenografted. Finally a fourth paragraph will address the topic of two techniques that have already shown excellent results in the area of skin thickness determination but for which no studied has yet been carried out to determine Breslow thickness although they do have the potential of doing so at least for thin melanoma (<1 mm): Optical Coherent Tomography (OCT) and Confocal Microscopy (CM).

3.1 In vivo techniques already available in clinics

3.1.1 Ultrasonography

3.1.1.1 Technical basis

Ultrasound is a longitudinal mechanical pressure wave. It is characterized by its velocity which has been reported for human skin, ranging from 1498 up to 1710 m/s (Agache and Humbert 2004). According to the information reported by Weichenthal (Weichenthal, Mohr et al. 2001), in the tissue of human skin affected by melanoma the ultrasound velocity deviates only by 1% from the value obtained in the case of healthy skin. If the ultrasound velocity is known, it is possible to calculate skin and/or tumour thickness *in vivo*, from the expression $l = v \cdot t/2$, where t is the time separating echoes generated by the external medium-epidermis interface and the dermis-subcutis interface, and v is ultrasonic velocity (Jasaitiene, Valiukeviciene et al. 2011).

3.1.1.2 Ultrasounds and skin interactions

Ultrasounds are characterized by frequencies between 20 kHz and 20 MHz. The choice of frequency impacts maximum penetration depth as well as axial resolution. Indeed ultrasound

attenuation A is proportional to frequency f : $A = A_0 \cdot f^\beta$ ($\beta \sim 1$ for soft tissues). Maximum thickness of human skin is 300 μm for epidermis and 2.5 mm for dermis (Moore, Lunt et al. 2003). Axial resolution λ is calculated as follows: $\lambda = v / f$. In the next paragraph several studies use different ultrasound frequencies that therefore influence measurements accuracy of Breslow index. To give the reader a rough idea of such possible axial resolutions: 79 μm and 21 μm using 20 MHz and 75 MHz ultrasounds respectively.

3.1.1.3 Non-invasive determination of Breslow index using ultrasonography (Guitera, Li et al. 2008; Machet, Belot et al. 2009; Vilana, Puig et al. 2009; Kaikaris, Samsanavicius et al. 2010)

In most studies evaluating sonography for measuring cutaneous lesions in the published literature, investigators used frequencies of 20 MHz or higher. However 20-MHz scanners are not available in many clinics or dermatology practices. But such studies using 10 MHz are as important as studies using 75 MHz ultrasounds even though they do not have the same goal. On the one hand, 10-MHz ultrasonography aims at distinguishing between thick (> 1 mm) and thin (< 1 mm) melanomas. Such a boundary is important in every day clinical practice for determining safety margins and for indication for SLNB in a potential one-time procedure; on the other hand, by increasing transducer frequency and as it increases axial resolution, technological advances can be expected to improve the accuracy of sonometric measurements of melanoma thinner than 1 mm. Another piece of information to keep in mind is that maximum penetration depth of 20- and 100-MHz ultrasounds is 7.6 mm and 1.5 mm respectively. Therefore, highest ultrasound frequencies may not be used to estimate melanomas thicker than 1.5 mm.

In order to evaluate the ability of ultrasonography to determine Breslow index, sonometric measurements are compared to the current gold-standard type of measurement: histometry, following a methodology described in previous paragraphs.

Correlation between sonometric and histometric results shows the relationship between investigation methods but not the sameness of separate examination results. Thus Bland and Altman (Bland and Altman 1986) created the Band and Altman graph that includes the numerical identity between the test results of two different methods. It uses the differences between the paired measurements and is suggested to be a more useful indication as to whether one method can be a valid substitution for another.

Melanomas generally appear as solid homogeneous hypoechoic lesions and naevi have a more irregular distributed internal echo. Dermis appears hyperechoic. When the tumours extend beyond the dermis-subcutis border, the demarcation may become difficult because apart from connective tissue septae, the subcutaneous fatty tissue is also hypoechoic. Also when lesions are that thin that they do not infiltrate the dermis, they can be invisible to ultrasonography. Other causes of discrepancies between sonometry and histometry are:

- Nevus cell collection beneath the melanoma,
- Hyperkeratosis that may cause overestimation,
- Anatomical location: strongest correlation for head and neck regions and overestimation for ear, genitalia or nail,
- Histological type: strongest correlation for nodular and superficial melanomas,
- Peritumoral reaction such as inflammatory infiltrate, fibrosis, neovascularisation and elastosis in the surrounding dermis are believed to overestimate thickness when measured with ultrasound since all these dermal modifications appear as hypoechoic, and

- Actinic damage (such as on face) resulting in subepidermal hypoechoic band result in overestimation.

General overestimation of sonometric results compared to histometric results may also be due to excision processing:

- Natural shrinkage of the skin occurring after excision, particularly evident for the dermis, and
- Routine histology using conventional formalin-paraffin processing frequently distorts the anatomy of the horny layer and may result in artefacts including shrinkage of the tissue.

Table 4 gives three examples of published results of comparison between histometry and sonometry in evaluating Breslow index.

| Reference | Ultrasound frequency | Mean difference between histometry and sonometry |
|----------------------------------|---------------------------------------|--|
| (Pellacani and Seidenari 2003) | 20 MHz | 6 μm |
| (Gambichler, Moussa et al. 2007) | 20 MHz vs. 100 MHz | 71 μm vs. 16.9 μm |
| (Vilana, Puig et al. 2009) | 14 MHz < 1 mm vs. < 2 mm > 2 mm | 60 μm 30 μm |

Table 4. Mean difference between histometric and sonometric measurements of melanoma thickness

3.1.1.4 Conclusion

The use of higher transducer frequencies (75-100 MHz) may further improve not only thickness measurements (particularly for melanomas < 1 mm) but also differentiate between malignant and benign melanocytic lesions. However limited availability of the high frequency ultrasound devices still precludes their widespread use. Rallan (Rallan, Dickson et al. 2006; Rallan, Bush et al. 2007) report that ultrasound imaging may help to differentiate benign pigmented lesions such as seborrheic keratosis, pigmented basal cell carcinoma or dermal nevus from melanoma but not atypical nevi from thin melanoma which is the main problem. Since accurate diagnosis of melanoma is mandatory before clinical management according to Breslow index determination, Doppler tool may be used to detect abnormal vascularisation which may help for differential diagnosis. Contrast agents may be used as well as other types of techniques based on light and that will be described in the next paragraphs: dermoscopy or confocal microscopy.

3.1.2 Dermoscopy

3.1.2.1 Light-skin interactions

Light is defined as electromagnetic waves that can be detected by human eye. Therefore light commonly includes electromagnetic waves whose wavelengths are between 380 and 760 nm long. Oftentimes ultraviolet (UV) as well as infrared (IR) radiation are included into so-called "light". Although such radiations are not visible they behave the same way as light from a geometrical optics point of view. As seen in Table 5, the International Commission on

Illumination (*Commission Internationale de l'Eclairage*, CIE) defines colours as spectral ranges within the light bandwidth.

| Colours | Spectral ranges (nm) |
|----------|----------------------|
| UVC | 250 – 280 |
| UVB | 280 – 315 |
| UVA | 315 – 380 |
| Violet | 380 – 439 |
| Blue | 439 – 498 |
| Green | 498 – 568 |
| Yellow | 568 – 592 |
| Orange | 592 – 631 |
| Red | 631 – 760 |
| Infrared | 760 – 25,000 |

Table 5. Spectral ranges defined by the International Commission on Illumination within the optical bandwidth

Skin is an optically inhomogeneous and absorbing media whose average refractive index is higher than that of air. This is responsible for partial reflection of the radiation at the tissue / air interface. Reflection from the surface of any flat material, where the angle of reflection is equal to the angle of incidence, is known as “specular reflection”. When the reflective surface is a bulk material, the reflection spectrum is governed by the Fresnel equations: as a result this type of reflection has been called Fresnel reflection (Griffiths and Haseth 2007). Bulk scattering is a major cause of dispersion of approximately 5 - 7% of the incident radiation (over the entire spectrum) in the backward direction.

The remaining part of the radiation penetrates the tissue. Multiple scattering and absorption are responsible for radiation broadening and decay as it travels through the tissue.

Two types of subsurface scattering occur within skin layers: Mie and Rayleigh scattering (Jacques 1996).

The first and outermost section of human skin is the stratum corneum, which is a stratified structure approximately 10 – 20 μm thick mainly composed of dead cells, called corneocytes, embedded in a particular lipid matrix. Light absorption is low in this tissue, with the amount of transmitted light being relatively uniform in the visible region of the light spectrum.

The epidermis is a 30 – 300 μm thick structure in which four layers can be distinguished from a cellular point of view. From bottom to top, keratinocytes start from undifferentiated cells (unipotent stem cells) to become specialized cells (corneocytes). The four layers each correspond to a different maturation step of keratinocytes along their ascension to the top:

- stratum basale includes unipotent stem cells that are each responsible for the renewal of a portion of the epidermis; they undergo asymmetric division: each stem cell gives rise to one daughter stem cell and another daughter cell that undergoes differentiation in starting its way towards the skin surface; besides keratinocytes stratum basale includes melanocytes but such cells' main role in light – skin interaction will be in explaining light absorption;
- stratum spinosum are given this name because keratinocytes look like spines,
- stratum granulosum; this name was given because of the keratin dots within the keratinocytes cytoplasm, and

- stratum lucidum that can be distinguished in thick skin (e.g. palm) composed of transparent epidermal cells with traces of nuclei.

The epidermis propagates and absorbs light. The absorption properties come from a natural chromophore: melanin produced by melanocytes then transmitted to melanosomes that lie within the stratum spinosum. Typically the volume fraction of the epidermis occupied by melanosomes varies from 1.3% (Fitzpatrick skin type I) to 43% (Fitzpatrick skin type VI). The dermis is a 600 – 2,500 μm thick structure which also propagates and absorbs light. It can be divided into two layers based on histological appearance:

- papillary dermis, and
- reticular dermis.

These layers are composed of connective tissue made of type I and III collagen and elastin, with nerves and blood vessels. Haemoglobin is a natural chromophore found in blood cells. In the arteries and in veins, 90-95% and 47% respectively of haemoglobin is oxygenated. These two types of haemoglobin, namely oxygenated and deoxygenated haemoglobin, have slightly different absorption spectra. Two other blood-derived pigments are found in the dermis: bilirubine and β -carotene (that may be found in the epidermis as well).

The hypodermis is a subcutaneous adipose tissue characterized by a negligible absorption of light (Technical report of A. Krishnaswamy and G.V.G. Baranowski, A study on skin optics, CS-2004-01).

3.1.2.2 Dermoscopy

Dermoscopy, also called dermatoscopy, epiluminescence microscopy or skin surface microscopy, was developed in the 1990s in order to augment the early diagnosis of melanoma. First technologies allowed the observer to examine pigmented skin lesions covered by a drop of oil and a glass slide through a stereo microscope. Then dermoscopy developed into a hand-held lighted magnifier to analyze skin lesions by observing newly defined and descriptively named subsurface structures: eg, dots, streaks, veils, and networks. The initial instruments used an oil or alcohol interface to decrease light reflection, refraction, and diffraction. This made the epidermis essentially translucent and allowed *in vivo* visualization of subsurface anatomic structures of the epidermis and papillary dermis that are otherwise not discernable to the unaided eye. Dermoscopes usually facilitate a 10-fold magnification of the skin. Newer instruments make the process easier to use by using cross-polarizing light filters which eliminate the need for oil or alcohol. Computer-based polarized light dermoscopes were lately commercialized (Rigel, Russak et al. 2010).

3.1.2.3. Breslow index determination based on dermoscopy

As described on the dermoscopy.org web site (Dermoscopy), dermoscopic criteria for the *in vivo* detection of melanoma depth are:

- pigment network: its occurrence inversely correlates with melanoma thickness,
- blue-whitish veil corresponds to an acanthotic epidermis with focal hypergranulosis above sheets of heavily pigmented melanocytes in the dermis. A blue-whitish veil is observed in 78% of melanomas > 0.75 mm thick and only in 21% of melanomas < 0.76 mm thick.
- Atypical vascular patterns are defined as vascular structures irregularly distributed throughout a given melanoma. Under this definition, atypical vascular patterns are seen in 66% of melanomas > 0.75 mm thick and only in 14% of melanomas < 0.76 mm thick.

Combinations of dermoscopic criteria along with clinical criteria such as clinical elevation, assessed as flat, palpable, or nodular and largest diameter have subsequently been proven to

increase accuracy in the preoperative evaluation of melanoma thickness. By subdividing all melanomas into two groups of less than, or greater than, 0.75 mm thickness, these combinations allow correct thickness predictions in 93% of thin non-metastazing (TnM) melanomas and 82% of melanomas > 0.75 mm for a total of 89% of cases (Argenziano, Fabbrocini et al. 1999). Carli et al showed that a 6.8 dermatoscopic score allowed a 79%-positive predictive value for classification of melanomas into two groups of Breslow index less than or greater than 0.55 mm (Carli, de Giorgi et al. 2000). However Haenssle (Haenssle, Korpas et al. 2009) chose to use the 7-point checklist as this algorithm can be learned and applied more easily by nonexperts (e.g., residents in dermatology) while still allowing a high sensitivity. They carried out a 10 year-prospective clinical study on 688 patients at increased melanoma risk detecting a total of 127 melanomas. This study showed no statistical significance in lower 7-point checklist score in melanoma *in situ* compared to invasive melanoma.

3.2 Diffuse Reflectance Spectroscopy (DRS)

Optical spectroscopy methods are based on interactions of light with biological tissues. During the past twenty years, Diffuse Reflectance (DR) and AutoFluorescence (AF) spectroscopies have been the most investigated spectroscopy modalities. DR spectroscopy is based on elastic scattering of photons within biological tissues. Elastic scattering is caused by variations in the refractive index of small particles in the medium, resulting in dispersion of light in all directions, without loss of energy, i.e. no wavelength shift between incident and reflected light. Different types and sizes of scattering centres can be found within the

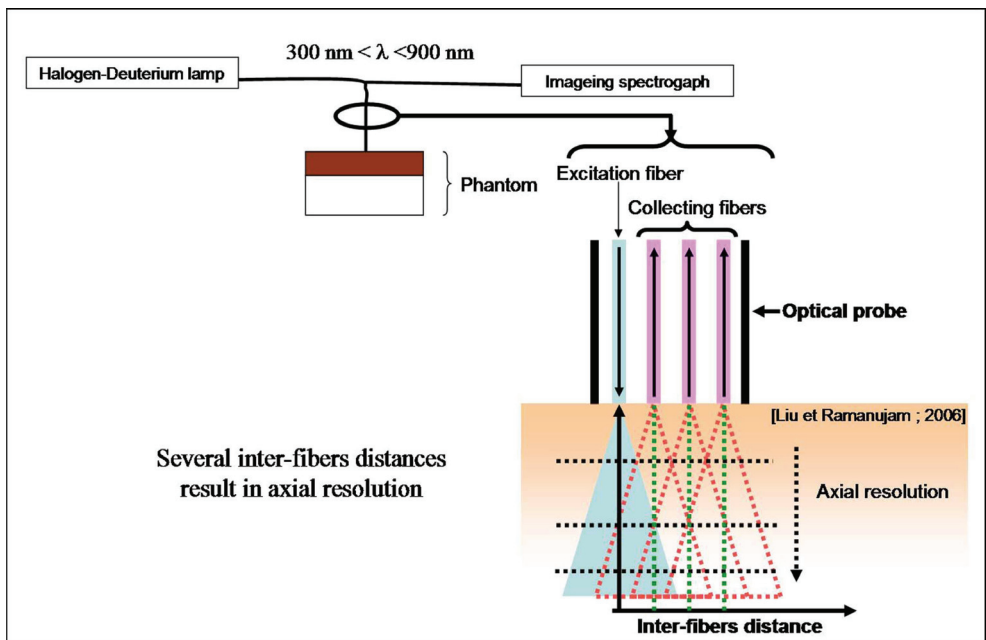


Fig. 1. Principle of axial resolution obtained thanks to several collecting optical fibres at several distances from the excitation optical fibre in Diffuse Reflectance Spectroscopy

tissue: collagen fibres, cellular membranes and subcellular structures (nuclei, mitochondria). As seen in figure 1, in order to use DR spectroscopy for Breslow index determination, Amouroux (Amouroux, Blondel et al. 2008) used several collecting optical fibres at different distances from the excitation optical fibre. Because of numerical aperture of optical fibres, the probing depth (different from the penetration depth) increases with inter-fibre distance. Of course this has limitation due to decreasing intensity with inter-fibre increase. It has been reported that excitations in the wavelength range 337 – 400 nm allow for probing depth of 225 – 250 μm in skin tissues with inter-fibres distance of 250 μm (Katika and Pilon 2006). To our knowledge, the only study on Breslow index determination using DRS was carried out on phantoms as a preliminary study prior to a clinical trial. Two-layer phantoms mimicking dermis (6.3 mm thick) for the bottom layer and melanoma (2, 3, 4, 5 and 6 mm) for the upper layer were made of gelatine as a solid 3D-matrix, intralipids for the scattering properties and coffee for the absorbing properties of melanoma. Based on the slopes of decreasing intensities recorded at the 5 different inter-fibre distances (271, 536, 834, 1076 and 1341 μm), the five different top layers' thicknesses could be discriminated. Further works need to discriminate thicknesses less than 1 mm which is at stake in clinical practice: 0.5, 1 and 1.5 mm for instance.

3.3 Techniques that have shown preliminary results

3.3.1 Infrared-microimaging

Absorption and scattering (Raman) infrared vibrational spectroscopies consist in determining vibrational frequencies of atoms within molecules giving access to information on that molecule's state and further on its environment for instance. Fourier Transform Infrared (FTI) spectroscopy can be performed directly on fixed and paraffin-embedded tissues without staining. Reports have shown the possibility to discriminate between melanoma and normal epidermis or between melanoma and benign nevi. In 2010, Ly (Ly, Cardot-Leccia et al. 2010), carried out the first study on the possibility by FTI spectroscopy to distinguish between the different types of melanoma and to identify IR specific signatures of dermatopathological parameters: ulceration, Breslow index, Clark level and number of mitoses per mm^2 . In each colour-coded image, pixels assigned to the same cluster represent an area of similar biochemical composition, producing an automated and objective digital staining of the sample. Ly et al found out that only one tumour cluster was observed for good prognosis melanomas whereas two or three clusters were simultaneously present for bad prognosis melanoma. However they still could not correlate such findings to Breslow index, even though Breslow index can be related to prognosis. Further studies will probably have to be carried out in order to determine whether or not it is possible to have an automated Breslow index determination through FIT extracted features. Such determination would spare a lot of time and would avoid Breslow index misdetermination if the section of the excised tumour is not made along the thickest part of the tumour.

3.3.2 Photoacoustic microscopy

Photoacoustic is a non-invasive imaging modality for imaging biological tissue structures by means of laser-induced ultrasound. Structures with optical absorption, such as blood vessels for instance, can be imaged with the spatial resolution of ultrasound. Lateral and axial resolutions as well as penetration depth were reported to be 45 μm , 15 μm and 3 mm respectively. Oh et al report good agreement with histometric measurements of melanomas

obtained on mice after human melanoma cells xenografted subcutaneously (Oh, Li et al. 2006).

3.4 Techniques that may have the potential to be used for Breslow index determination

Optical Coherence Tomography (OCT) as well as Confocal Microscopy (CM) are widely used techniques used for skin thicknesses (epidermis, dermis, etc.) measurements. However, probably because of their low penetration depth (1 mm and 0.3 mm respectively), they have not been studied in the context of Breslow index determination yet. But as we will see in the next paragraph, they could potentially address determination of thin melanomas especially since they provide good accuracy in differential diagnosis of pigmented skin lesions.

3.4.1 Optical Coherence Tomography (OCT)

Different terms are employed in the literature to specify this method on investigations: dual-beam coherent interferometry or laser Doppler interferometry, optical coherence tomography (OCT) or optical coherence reflectometry. OCT is analogous to ultrasonic imaging, which measures the intensity of reflected infrared light rather than reflected sound waves from the sample. Time gating is employed so that the time for the light to be reflected back (or echo delay time) is used to assess the intensity of back-reflection as a function of depth. Unlike ultrasound, the echo time delay on the order of femtoseconds cannot be measured electronically due to the high speed associated with the propagation of light. Therefore, a time-of-flight technique has to be engaged to measure such an ultrashort time delay of light back-reflected from the different depth of a sample. OCT uses an optical interferometer illuminated by a low-coherent-light source so solve this problem (Tuchin 2007).

To our knowledge, no study has yet addressed the issue of Breslow index determination using OCT. Only one study tried to determine OCT specific features of benign and malignant melanocytic skin lesions. OCT of benign nevi demonstrated correlates of typical histological features including the finger-shaped elongation of rete ridges and dense cell clusters in the dermoepidermal junction zone and/or dermis. OCT features of malignant melanoma were large vertically arranged icicle-shaped structures, which mainly corresponded to dense dermal infiltrates of melanocytes as confirmed by histology. However Gambichler (Gambichler, Regeniter et al. 2007) were not able to detect any definitive features in OCT images enabling to differentiate tumour subtypes and tumour stages, e.g. thin *vs.* thick melanomas. The latter observation is, however, not surprising because the penetration depth of current OCT techniques is limited to about 1 mm in highly turbid media such as human skin. However, the greatest challenge in the diagnosis of malignant melanoma represents the discrimination of early melanomas (<1 mm) from benign nevi, for example. OCT techniques that provide a depth of penetration of approximately 1 mm potentially address the aforementioned diagnostic issue.

3.4.2 Confocal microscopy (CM)

Confocal Scanning Laser Microscopy (CLSM) is a non-invasive technique that provides real-time *in vivo* imaging of skin lesions at variable depths in horizontal planes equivalent to the resolution of conventional microscopes. With this technique, a beam splitter separates the light mixture from the laser by allowing only laser light to pass through while reflecting

fluorescence light onto a detection apparatus with a pinhole-sized spatial filter. Scattered photons can be selected from a given volume. The great advantage of a confocal microscope is that axial resolution is enhanced, which results in the "optical sectioning" capability. Reflectance Confocal Microscopy (RCM) allows a higher resolution analysis of dermoscopic features than does CLSM but is more technically sensitive and expensive to use and is not as effective in analyzing deeper structures. RCM can assess microanatomical structures to a depth of only 300 μm (Tuchin 2007; Rigel, Russak et al. 2010).

In a study aiming at evaluating RCM as a secondary source of information for pigmented skin lesions after clinical (naked eye) and dermoscopic evaluations, Guitera (Guitera, Pellacani et al. 2009) found out RCM examination was particularly accurate for light-colored lesions. This is of utmost medical value since such lesions are well-known clinical and dermoscopy challenges. RCM helps improve specificity thus dramatically reducing the rate of benign lesions excisions by 23% for the current study. A 98%-sensitivity is reached when clinically suspicious lesions were assessed for diagnosis by combining dermoscopy and RCM.

4. Conclusion

Non-invasive Breslow index determination would allow one-time procedure for melanoma clinical management which would be of utmost medical interest for several reasons: unimpaired sentinel lymph node status, low morbidity, pain and stress associated to surgical excision margins. However, as explained throughout the current chapter, such a determination requires melanoma diagnosis prior to Breslow determination. As a result, all techniques reported in this chapter (based on ultrasounds, optical waves or both), not only demonstrate their ability to determine Breslow thickness but also how they increase diagnosis accuracy. Therefore, as previously mentioned (studies combining confocal microscopy and dermoscopy or ultrasounds and optical microscopy), the key for an optimal melanoma management in a clinical environment might be to combine different of the aforementioned techniques and see which combination would allow not only an accurate melanoma diagnosis but also a precise Breslow index determination. Studies should now be carried out in this philosophy.

5. Reference

- Agache, P. and P. Humbert (2004). *Measuring the skin*. Berlin, Spring-Verlag.
- Agnese, D. M., S. F. Abdessalam, et al. (2003). "Cost-effectiveness of sentinel lymph node biopsy in thin melanomas." *Surgery* 134(4): 542-7; discussion 547-8.
- Amouroux, M., W. C. Blondel, et al. (2008). "A preliminary study on skin phantoms to test spatially resolved-Diffuse Reflectance Spectroscopy as a tool to help diagnose cutaneous melanoma: A non-invasive measurement of Breslow index." *Biomed Mater Eng* 18(4-5): 339-43.
- Argenziano, G., G. Fabbrocini, et al. (1999). "Clinical and dermatoscopic criteria for the preoperative evaluation of cutaneous melanoma thickness." *J Am Acad Dermatol* 40(1): 61-8.
- Balch, C. M., J. E. Gershenwald, et al. (2009). "Final version of 2009 AJCC melanoma staging and classification." *J Clin Oncol* 27(36): 6199-206.
- Bland, J. M. and D. G. Altman (1986). "Statistical methods for assessing agreement between two methods of clinical measurement." *Lancet* 1(8476): 307-10.

- Breslow, A. (1970). "Thickness, cross-sectional areas and depth of invasion in the prognosis of cutaneous melanoma." *Ann Surg* 172(5): 902-8.
- Breslow, A. (1975). "Tumor thickness, level of invasion and node dissection in stage I cutaneous melanoma." *Ann Surg* 182(5): 572-5.
- Carli, P., V. de Giorgi, et al. (2000). "Preoperative assessment of melanoma thickness by ABCD score of dermatoscopy." *J Am Acad Dermatol* 43(3): 459-66.
- Cascinelli, N., E. Bombardieri, et al. (2006). "Sentinel and nonsentinel node status in stage IB and II melanoma patients: two-step prognostic indicators of survival." *J Clin Oncol* 24(27): 4464-71.
- Daley, M. D., P. H. Norman, et al. (2004). "Adverse events associated with the intraoperative injection of isosulfan blue." *J Clin Anesth* 16(5): 332-41.
- Dermoscopy, I. S. o. "Dermoscopy tutorial: measurement of melanoma thickness, http://www.dermoscopy.org/atlas/5step/description_d.htm." Retrieved March, 29, 2011.
- Gambichler, T., G. Moussa, et al. (2007). "Preoperative ultrasonic assessment of thin melanocytic skin lesions using a 100-MHz ultrasound transducer: a comparative study." *Dermatol Surg* 33(7): 818-24.
- Gambichler, T., P. Regeniter, et al. (2007). "Characterization of benign and malignant melanocytic skin lesions using optical coherence tomography in vivo." *J Am Acad Dermatol* 57(4): 629-37.
- Gannon, C. J., D. L. Rousseau, Jr., et al. (2006). "Accuracy of lymphatic mapping and sentinel lymph node biopsy after previous wide local excision in patients with primary melanoma." *Cancer* 107(11): 2647-52.
- Garbe, C., K. Peris, et al. (2009). "Diagnosis and treatment of melanoma: European consensus-based interdisciplinary guideline." *Eur J Cancer* 46(2): 270-83.
- Griffiths, P. R. and J. A. D. Haseth (2007). *Fourier Transform infrared spectrometry*. Canada, John Wiley and Sons.
- Guitera, P., L. X. Li, et al. (2008). "Melanoma histological Breslow thickness predicted by 75-MHz ultrasonography." *Br J Dermatol* 159(2): 364-9.
- Guitera, P., G. Pellacani, et al. (2009). "In vivo reflectance confocal microscopy enhances secondary evaluation of melanocytic lesions." *J Invest Dermatol* 129(1): 131-8.
- Haenssle, H. A., B. Korpas, et al. (2009). "Seven-point checklist for dermatoscopy: performance during 10 years of prospective surveillance of patients at increased melanoma risk." *J Am Acad Dermatol* 62(5): 785-93.
- Jacques, S. (1996). "Origins of tissue optical properties in the uva visible and nir regions." *OSA TOPS on Advances in Optical imaging and Photon Migration* 2: 364-369.
- Jasaitiene, D., S. Valiukeviciene, et al. (2011). "Principles of high-frequency ultrasonography for investigation of skin pathology." *J Eur Acad Dermatol Venereol* 25(4): 375-82.
- Johnson, T. M., V. K. Sondak, et al. (2006). "The role of sentinel lymph node biopsy for melanoma: evidence assessment." *J Am Acad Dermatol* 54(1): 19-27.
- Kaikaris, V., D. Samsanavicius, et al. (2010). "Measurement of melanoma thickness - comparison of two methods: ultrasound versus morphology." *J Plast Reconstr Aesthet Surg*.
- Katika, K. M. and L. Pilon (2006). "Steady-state directional diffuse reflectance and fluorescence of human skin." *Appl Opt* 45(17): 4174-83.
- Khorshid, S. M., E. Pinney, et al. (1998). "Melanoma excision by general practitioners in north-east Thames region, England." *Br J Dermatol* 138(3): 412-7.

- Lens, M. B., P. Nathan, et al. (2007). "Excision margins for primary cutaneous melanoma: updated pooled analysis of randomized controlled trials." *Arch Surg* 142(9): 885-91; discussion 891-3.
- Ly, E., N. Cardot-Leccia, et al. (2010). "Histopathological characterization of primary cutaneous melanoma using infrared microimaging: a proof-of-concept study." *Br J Dermatol* 162(6): 1316-23.
- Machet, L., V. Belot, et al. (2009). "Preoperative measurement of thickness of cutaneous melanoma using high-resolution 20 MHz ultrasound imaging: A monocenter prospective study and systematic review of the literature." *Ultrasound Med Biol* 35(9): 1411-20.
- McCready, D. R., D. M. Ghazarian, et al. (2001). "Sentinel lymph-node biopsy after previous wide local excision for melanoma." *Can J Surg* 44(6): 432-4.
- Moore, T. L., M. Lunt, et al. (2003). "Seventeen-point dermal ultrasound scoring system--a reliable measure of skin thickness in patients with systemic sclerosis." *Rheumatology (Oxford)* 42(12): 1559-63.
- Ng, P. C., D. A. Barzilai, et al. (2003). "Evaluating invasive cutaneous melanoma: is the initial biopsy representative of the final depth?" *J Am Acad Dermatol* 48(3): 420-4.
- Oh, J. T., M. L. Li, et al. (2006). "Three-dimensional imaging of skin melanoma in vivo by dual-wavelength photoacoustic microscopy." *J Biomed Opt* 11(3): 34032.
- Paek, S. C., K. A. Griffith, et al. (2007). "The impact of factors beyond Breslow depth on predicting sentinel lymph node positivity in melanoma." *Cancer* 109(1): 100-8.
- Pellacani, G. and S. Seidenari (2003). "Preoperative melanoma thickness determination by 20-MHz sonography and digital videomicroscopy in combination." *Arch Dermatol* 139(3): 293-8.
- Rallan, D., N. L. Bush, et al. (2007). "Quantitative discrimination of pigmented lesions using three-dimensional high-resolution ultrasound reflex transmission imaging." *J Invest Dermatol* 127(1): 189-95.
- Rallan, D., M. Dickson, et al. (2006). "High-resolution ultrasound reflex transmission imaging and digital photography: potential tools for the quantitative assessment of pigmented lesions." *Skin Res Technol* 12(1): 50-9.
- Ranieri, J. M., J. D. Wagner, et al. (2006). "The prognostic importance of sentinel lymph node biopsy in thin melanoma." *Ann Surg Oncol* 13(7): 927-32.
- Rigel, D. S., J. Russak, et al. (2010). "The evolution of melanoma diagnosis: 25 years beyond the ABCDs." *CA Cancer J Clin* 60(5): 301-16.
- Ruiter, D. J., A. Spatz, et al. (2002). "Pathologic staging of melanoma." *Semin Oncol* 29(4): 370-81.
- Tichy, M., D. Ditrichova, et al. (2007). "Double skin tumors with an atypical clinical picture." *Acta Dermatovenerol Alp Panonica Adriat* 16(2): 63-6.
- Tuchin, V. V. (2007). *Tissue optics: light scatterig methods and instruments for medical diagnosis*. Bellingham (WA), SPIE.
- Vilana, R., S. Puig, et al. (2009). "Preoperative assessment of cutaneous melanoma thickness using 10-MHz sonography." *AJR Am J Roentgenol* 193(3): 639-43.
- Wagner, J. D., J. Ranieri, et al. (2003). "Patterns of initial recurrence and prognosis after sentinel lymph node biopsy and selective lymphadenectomy for melanoma." *Plast Reconstr Surg* 112(2): 486-97.
- Weichenthal, M., P. Mohr, et al. (2001). "The velocity of ultrasound in human primary melanoma tissue - implications for the clinical use of high resolution sonography." *BMC Dermatol* 1: 1.