



Sept 2008

**EFFICACY OF INTRACEREBRAL DELIVERY OF CARBOPLATIN IN  
COMBINATION WITH PHOTON IRRADIATION FOR TREATMENT OF F98  
GLIOMA-BEARING RATS.\***

Julia Rousseau, Ph.D.<sup>1,2,3</sup>, Rolf F. Barth, M.D.<sup>4</sup>, Melvin L. Moeschberger, Ph.D.<sup>4</sup>,  
and Hélène Elleaume, Ph.D.<sup>1,2,3,5</sup>.

<sup>1</sup> INSERM U836, Equipe 6, Grenoble, France;

<sup>2</sup> Université Joseph Fourier, Grenoble, France;

<sup>3</sup> European Synchrotron Radiation Facility, Grenoble, France;

<sup>4</sup> Department of Pathology and Division of Biostatistics, The Ohio State University, Columbus,  
Ohio 43210;

<sup>5</sup> Centre Hospitalier Universitaire, Grenoble, France;

Corresponding Author:

Hélène Elleaume, Ph.D., INSERM Unité 836, ESRF, Medical Beamline, BP 220, 38043  
Grenoble Cedex 9, France. Tel: (+33) 4-7688-2343; Fax: (+33) 4-7688-2885;

E-mail: [h.elleaume@esrf.fr](mailto:h.elleaume@esrf.fr)

Keywords: F98 rat glioma, carboplatin, intracerebral delivery, osmotic pumps, radiotherapy.

Short title: Efficacy of radiotherapy combined with prolonged i.c. delivery of carboplatin against  
F98 rat-glioma.

\*Presented in part at the Annual Meeting of the American Association for Cancer Research, San  
Diego, CA, 2008.

**Acknowledgments:** We thank the European Synchrotron Radiation Facility for providing beam time; Mrs. Massart, Mr. Brochard, Dr. Nemoz for help during the experiments; Mr. Dallery for animal care; Dr. Charley for providing carboplatin; Ms. Martz for secretarial assistance and Mr. Scully for photographic assistance. R.F.B. acknowledges the support of N.I.H. grant 1-R01-CA09845 and the Department of Pathology and a Research Investment Fund grant from The Ohio State University College of Medicine.

**Conflicts of interest.** There are no conflicts of interest.

## Abstract

**Purpose:** To evaluate the efficacy of prolonged intracerebral (i.c.) administration of carboplatin by means of ALZET<sup>TM</sup> osmotic pumps, in combination with radiotherapy for the treatment of intracranial F98 glioma-bearing rats.

**Experimental Design:** Seven days after stereotactic implantation of F98 glioma cells into the brains of Fischer rats, carboplatin was administered i.c. by means of ALZET<sup>TM</sup> pumps over 6 days. Rats were treated at the European Synchrotron Radiation Facility (ESRF) with a single 15 Gy X-rays dose, either given alone or 24 hours after the administration of carboplatin.

**Results:** Untreated rats had a mean survival time (MST)  $\pm$  standard error of  $23\pm 1$  d. compared to  $44\pm 3$  d. for X-irradiated animals, and  $69\pm 20$  d. for rats that received carboplatin alone, with 3 of 13 of these surviving  $>195$  d. Rats that had received carboplatin, followed by X-irradiation, had a MST of  $>142\pm 21$  d. and a median survival time (MeST) of  $>195$  d., with 6 of 11 rats (55%) still alive at the time of euthanization. The corresponding percentage increase in lifespan, based on the MeSTs, were 25%, 85% and 713%, respectively, for carboplatin alone, radiotherapy alone or the combination.

**Conclusions:** Our data demonstrate that i.c. infusion of carboplatin by means of ALZET<sup>TM</sup> pumps in combination with X-irradiation is highly effective for the treatment of the F98 glioma. They provide strong support for the approach of concomitantly administering chemo- and radiotherapy for the treatment of brain tumors.

## Introduction

Despite multimodality treatment strategies that combine surgery, chemotherapy, and radiotherapy, high grade gliomas are almost uniformly fatal (1). One of the most important advances in the treatment of glioblastoma multiforme (GBM) over the past 20 years has been the introduction of temozolomide in combination with photon irradiation, followed by repetitive cycles of temozolomide. Although a significant subset of patients were survivors at 24 months, the overall increase in median lifespan of GBM patients was only 2.5 months (2) indicating that there still is an urgent need to develop innovative therapeutic approaches to treat brain tumors.

Experimental types of radiation therapy based on diverse physical principles, such as boron neutron capture therapy (BNCT) (3) and stereotactic synchrotron radiotherapy (SSR) (4-6), are among those under investigation. Recently, we have reported on the therapeutic efficacy of intratumoral (i.t.) administration of carboplatin by convection-enhanced delivery (CED), followed by irradiation with either 80keV synchrotron X-rays (SSR) or 6MV (LINAC) photons for the treatment of the invariably fatal F98 rat glioma (6). These studies showed that either type of chemo-radiotherapy produced significant prolongations of survival times of F98 glioma-bearing rats with subsets of long-term (>200 days) survivors (6). Similar results were obtained with i.t. delivery of cisplatin by CED in combination with either synchrotron X-rays or 6MV photon irradiations<sup>1</sup>.

Cisplatin and carboplatin are highly effective anti-cancer drugs that have been used clinically to treat various malignancies (7). The formation of platinum adducts with DNA can interfere with the repair of radiation-induced damage, which could explain the synergistic interaction between either cisplatin or carboplatin and ionizing radiation (8). The clinical use of systematically administered platinated drugs to treat patients with brain tumors has been

---

<sup>1</sup> Rousseau, J., Barth, R.F. and Elleaume, H. Unpublished data

limited, by their systemic toxicity, but also by their poor ability to penetrate an intact blood-brain barrier (BBB) in areas where there are microinvasive deposits of tumor (9). Several approaches have been proposed to bypass the BBB and deliver anticancer drugs directly to the tumor, thereby increasing tumor drug concentrations and reducing the systemic toxicity. These methods include CED of drugs via catheters placed into the tumor (10), or surgical implantation of drug-loaded polymer matrices in the brain (11-14). At least with chemosensitive tumors, there has been a clear relationship between the therapeutic response and increasing both the concentration and duration of exposure to carboplatin (12, 13) or cisplatin (15). Using the RG2 model implanted in rats, Emerich *et al.* have shown that sustained delivery of carboplatin with biodegradable microspheres placed into the tumor produced significantly greater improvements in survival than equipotent bolus injections (13). Similarly, Carson *et al.* have shown that carboplatin, delivered by osmotic-pumps into the brainstems of rats bearing F98-gliomas, significantly enhanced their survival (16-18). In the present study, we have used carboplatin because it has been shown to be tumoricidal against gliomas both *in vitro* and *in vivo* (6, 7, 12, 19) and it was less neurotoxic than cisplatin (20) when delivered i.c. to rats and monkeys (12, 16, 20-22). As described in detail below, we show that a 6-day i.t. infusion of carboplatin using osmotic pumps, combined with SSR was highly effective in prolonging survival and even curing F98 glioma-bearing rats.

## Materials and Methods

### *Tumor model.*

The F98 rat glioma simulates human GBMs in several important ways (23), including its infiltrative pattern of growth within the brain and lack of a curative response to a variety of therapeutic modalities, except for BNCT (24) and our recent studies using i.c. delivery of cis- or carboplatin combined with either synchrotron or megavoltage X-irradiation (5, 6). F98

glioma cells (CRL-2397, American-Type-Culture-Collection, Manassus, VA) were cultured in Dulbecco's Modified Eagle's Medium (DMEM), supplemented with 10% fetal calf serum. For tumor cells implantation rats were anesthetized with isoflurane, followed by an intraperitoneal injection of ketamine (60 mg/kg body weight [b.w.]) and xylazine (7 mg/kg b.w.) The animals' eyes were coated with an ocular lubricant to prevent keratitis. A 10 $\mu$ L suspension of either 1,000 or 4,000 F98 cells in serum-free DMEM containing 1% agarose (gelling temperature <30°C), was injected stereotactically into the right caudate nucleus using a syringe pump (KDS310, GENEQ Inc., Montréal, Canada). This was mounted on a stereotactic headframe (David-Kopf-Instruments, Tujunga, California) and a Hamilton syringe (702N) was secured to the pump. The cells were injected over 16sec. via a 22-gauge needle, which was inserted 3.5mm to the right of the bregma to a depth of 5.5mm from the skull and then withdrawn to its target depth of 5.0mm. Following implantation, the needle was left in place for 2 minutes and then withdrawn slowly. The hole in the calvarium was filled with bone wax and the operative field was cleaned with betadine before closure of the scalp incision. All operative procedures and animal care were carried out in conformity with the guidelines of the French Government (decree 87-848, 1987, license 7593 and A38071).

### ***Chemotherapy.***

Carboplatin (M.W. 371.25; Faulding-Pharmaceuticals S.A, Asnières, France) was diluted in 5% dextrose (Laboratoire-Aguettant, Lyon, France) to obtain a final concentration of 0.5mg/mL. ALZET<sup>TM</sup> osmotic pumps (model #2001) and brain infusion kits (model #2, rigid stainless-steel cannula, 5mm, 28-gauge) (Charles-River Laboratories, L'Abresles, France) were assembled and filled with carboplatin. The pumps were stored in the dark at 37°C for 24h prior to their use in a sterile solution of 0.9% saline. Seven days after tumor implantation the animals were anesthetized and the scalp re-opened. The bone wax was removed with a

needle and the infusion cannula was advanced to a depth of 5mm through the hole made for tumor cell inoculation. The brain infusion kit was fixed in place with surgical glue and the pump was implanted in a subcutaneous pocket, in the mid-scapular region with a sufficient amount of catheter tubing to permit free motion of the animal's head and neck. The pumps were left in place from days 7 to 13, during which time the animals received an infusion of 144 $\mu$ L of either carboplatin (72 $\mu$ g, 194 nmol) or 5% dextrose, delivered at a flow rate of 1 $\mu$ L/h over 6 days, following which the pumps were removed.

### ***X-irradiations.***

Stereotactic synchrotron radiotherapy was carried out at the ESRF as previously described (4, 5). A single 15 Gy dose was delivered on day 14 after tumor implantation, using monochromatic 78.8keV X-rays (80eV energy-bandwidth) (25). The right cerebral hemisphere was centred on the rotation axis of the irradiation system and the beam was shaped to 10mm in width and 1mm in height. The dose was delivered while the rat was being rotated, and translating upwards between each of the adjacent 360° arcs so that the irradiated target volume encompassed a cylinder 10mm in diameter and 13 to 15mm in height. The X-ray dose rate of 0.3Gy/s was determined using an ion chamber (Unidos, PTW, Freiburg, Germany). Contrast-enhanced imaging was performed by synchrotron computed tomography (SRCT), 15 to 18 days after implantation to confirm the presence of tumor.

### ***Experimental groups.***

Initially we evaluated the safety and efficacy of chemotherapy and radiotherapy treatments administered independently. In this study, 4,000 F98 cells were implanted into the brains of male Fischer rats weighing 230-260 g (Charles-River Laboratories, L'Abresles, France). The animals were stratified into four groups, and treated as indicated following tumor (day 0) implantation: Group 1: Untreated controls; Group 2 received a 6-day infusion

of carboplatin (144 $\mu$ L containing 72 $\mu$ g) beginning on day 7; Group 3 received a single fraction of 15 Gy on day 14; Group 4 (excipient control) received a 6-day infusion of 5% dextrose alone, which had been used for the dilution of carboplatin, beginning on day 7, in combination with a single 15 Gy dose of X-rays on day 14 (Table 1).

In the second study, we evaluated the combination of chemotherapy and X-irradiation. The tumors were established by implanting 1,000 F98 cells i.c. The animals were randomized into 4 experimental groups, as follows: Group 5: Untreated-controls; Group 6: Chemotherapy alone; Group 7: X-irradiation alone; Group 8: Chemotherapy in combination with X-irradiation, 24 h after completion of infusion (Table 2).

#### ***Monitoring of clinical status and histopathology.***

After therapy, the animals were weighed 3X per week and their clinical status was monitored until the end of the study (200 d. and 195 d., in the first and second experiment, respectively). Those animals showing a combination of sustained weight loss, ataxia and peri-orbital hemorrhage were euthanized by intracardiac injection of Dolethal (150 mg/kg; Vetoquinol, Lure, France). The brains were fixed in 10% buffered formalin, and cut coronally at the level of the optic chiasm and 2mm anterior and posterior to it. Slices were embedded in paraffin, sectioned at 4 $\mu$ m, stained with hematoxylin and eosin (H&E), and examined microscopically to assess histopathologic changes. The tumor size index (TSI) was determined from H&E stained coronal sections, using a semi-quantitative grading scale ranging from 0 to 4, as follows: 0, no tumor; 1, very small (<1mm); 2, small (~1-3 mm); 3, large (~4-7 mm); and 4, massive (>8mm).

#### ***Statistical evaluation of survival data.***

Kaplan-Meier survival curves were plotted for each group. Differences between groups were assessed for statistical significance by means of the log-rank test (JMP®, SAS-Institute-

Inc., Cary, NC) or in the case of crossing survival curves, a modification of the Cox proportional hazards model was used to allow for non-proportional hazards (26). Minimal statistical significance was defined at  $p < 0.05$ . Those rats still alive at the end of the study were euthanized. The mean survival times (MST), standard errors (SE), and median survival times (MeST) were calculated using the euthanization date for rats that were still alive at the end of the study (censored data). Percent increased lifespan (%ILS) was determined relative to MST or MeST of untreated controls as previously described (6). In those instances where censored data were used to calculate the MST, the “true” MST actually would have been larger. Although there are methods that can be used to estimate the “true” MST, this would have required a number of assumptions. Therefore, we have chosen to record the arithmetic mean even though this underestimated the true mean.

## Results

### *Therapeutic response following chemotherapy or X-irradiation alone.*

Surgery for pump implantation was well tolerated. Although the animals lost  $\leq 10\%$  of their body weight within 7 days following initiation of chemotherapy, it subsequently was regained and clinically the animals appeared to be normal. Survival data and Kaplan-Meier plots for animals that received chemotherapy alone or X-irradiation alone are shown in Table 1 and Fig. 1, respectively. The survival plots of all treatment groups were significantly different from the untreated controls ( $p < 0.001$ ). The  $MST \pm SE$  of untreated controls was  $22 \pm 1$  d. post tumor implantation compared to  $38 \pm 2$  d. for rats that received irradiation alone, and the MST of the latter was not significantly different ( $p = 0.51$ ) from animals that received infusion of 5% dextrose followed by X-irradiation ( $34 \pm 2$  d.). Rats that received carboplatin alone had a MeST of 82 d. and a censored MST of  $84 \pm 18$  d. The corresponding %ILS relative to the median was 273%, there was one cured animal in this group.

### *Therapeutic response following chemo-radiotherapy.*

Survival data following chemo-radiotherapy are summarized in Table 2 and Kaplan-Meier survival plots are shown in Fig. 2. The survival plots of all treatment groups were significantly different from that of the untreated controls ( $p < 0.0015$ ). Untreated rats had a MST of  $23 \pm 1$  d. compared with  $44 \pm 3$  d. for X-irradiated animals. Rats which had received carboplatin alone, had a MeST of 30 d. and a censored MST of  $69 \pm 20$  d., with 3 rats surviving  $> 195$  days, at which time the study was terminated. Animals that had received carboplatin, followed by X-irradiation, had a MST of  $> 142 \pm 21$  d. and a MeST of  $> 195$  d., with 6 of 11 rats (55%) alive at the end of the study. This was significantly different from irradiated animals ( $p = 0.0014$ ) or those that received carboplatin alone ( $p = 0.0472$ ). The corresponding %ILSs, based on the MeSTs, were 25%, 85% and 713% (censored) for

carboplatin alone, radiotherapy alone or chemo-radiotherapy, respectively. It is noteworthy that in the chemo-radiotherapy group, 8 of 11 rats (73%) were still alive at day 100.

### ***Neuropathologic evaluation.***

In the first experiment (Table 1), rats that received 5% dextrose as an excipient control, followed by X-irradiation, all had large to massive tumors (TSI=3.13), the histology of which was similar to that of untreated animals, and to those that received X-irradiation alone. Six out of 9 animals that received carboplatin had large to massive tumors with central necrotic zone (TSI=2.44). One animal in this group had no evidence of tumor at the end of the study and was regarded as cured (Fig. 3B).

In the second experiment (Table 2), five of 13 rats that received carboplatin alone, showed no macro- or microscopic evidence of tumor (TSI=1.69), although two brains showed marked dilatation of the lateral ventricles. Microscopic findings in the brains of cured animals included focal accumulations of macrophages with some intracellular dystrophic deposits of calcium, occasional giant cells and microscopic porencephalic cysts (Figs. 3C, 3D). There was moderate flattening of choroidal epithelial cells lining the lateral ventricle of the tumor bearing cerebral hemisphere in the brains of cured animals suggesting that this may have been due to a drug effect. Four rats that had been treated with 15Gy had tumors, some of which were large (TSI=3.25). The brains of the 4 other rats from this group were not available for neuropathologic evaluation. Rats that had received carboplatin in combination with X-irradiation had the best response to therapy (TSI=0.63; Table 2 and Fig. 2). A total of 7 out of 11 animals had no microscopic evidence of residual tumor. Several of the cured rats' brains showed right ventricular dilatation, suggesting that they may have had partial aqueductal obstruction at some point in time, and several others had microscopic porencephalic cysts that were surrounded by a light scattering of hemosiderin-laden macrophages. There was mild to moderate flattening of choroidal epithelial cells lining the

lateral ventricles of the tumor bearing cerebral hemisphere of some animals suggesting a drug radiation related effect (27). In contrast, untreated control animals had large (TSI=3.4) infiltrative tumors, which invaded both gray and white matter.

## Discussion

In the present study, we have evaluated the therapeutic efficacy of prolonged i.c. infusions of carboplatin in combination with photon irradiation. First, we showed that infusions of carboplatin alone, and infusions of 5% dextrose in combination with X-irradiation, were well tolerated. As expected, the Kaplan-Meier survival plots of animals that had received 5% dextrose (vehicle for carboplatin infusions) in combination with X-irradiation was not statistically different from that of X-irradiated rats ( $p=0.51$ ) and all of these animals died within <50 days following tumor implantation. The censored MST of 9 animals that had received carboplatin alone was  $84\pm 18$  d. with one long-term survivor. In the second study, the group, which had received the same chemotherapeutic regimen, had a censored MST of  $69\pm 20$  d. and 3 of 13 rats were long-term survivors (Table 2). Chemotherapy alone improved the survival of F98 glioma-bearing rats, and this was further enhanced by the addition of X-irradiation. The combination of treatments was the most effective protocol with 55% long-term survivors and 73% of the rats alive at 100 days.

Our results demonstrate the therapeutic efficacy of i.c. administration of carboplatin in combination with X-irradiation for the treatment of F98 glioma-bearing rats. Comparable survival data have been obtained by us that confirm those reported here. With similar treatment conditions, F98 glioma-bearing rats that had received prolonged infusion of carboplatin in combination with X-irradiation had  $MST > 117\pm 9$  d. (5/12 rats were still alive 200 d. after tumor implantation) compared to  $22\pm 2$  d. for untreated animals<sup>2</sup>.

---

<sup>2</sup> Rousseau, J., Barth, R.F. and Elleaume, H. Unpublished data.

In comparison to that which we previously have reported (6), we observed that the initiation of treatment 7 d. rather than 13 d. following tumor implantation, combined with prolonged infusion of carboplatin further improved survival (MeST of >195 d. *versus* 60d., previously). However, a direct comparison between these studies is difficult because delivery and schedule of irradiations were different: 1×15 Gy *versus* 3×8 Gy and 72μg of carboplatin delivered over 6 days *versus* 20μg of carboplatin over 40 minutes. Chemotherapy for the short-term infusions (6) was initiated 13d. after tumor implantation at which time the tumors had a volume of ~20-25mm<sup>3</sup>, as determined by SRCT or MRI (28), whereas in the present study, it was started on day 7 at a point in time that the tumor would not have been detectable by SRCT or MRI. Therefore, it was not unexpected that the MSTs were longer since it is well recognized that the earlier treatment is initiated, the better the therapeutic response. This is supported by our own recent experimental data showing that if treatment with carboplatin, followed by 6MV X-irradiation was delayed until d. 17, at which time the tumor volume was ~60-80 mm<sup>3</sup>, the prolongation in MSTs were significantly less than those observed in animals whose treatment was started on d. 13 following implantation<sup>3</sup>. Firm conclusions can not be drawn on the fundamental mechanism of effects and further studies will be carried out to evaluate the importance of these various parameters.

To the best of our knowledge, only two clinical reports describe the direct i.c. infusion of platinated drugs for glioma treatment (14, 29). Using 68 catheters, Bouvier *et al.* infused 8.2mg of cisplatin over 10 days to treat a patient with recurrent malignant glioma. There were no adverse side effects associated with, chemotherapy, catheter implantation or removal. Although chemotherapy halted progression of the tumor, it recurred, and the patient died 6 months later (29). In the other study, Sheleg *et al.* administered cisplatin, incorporated into biodegradable polymers, after subtotal resection of the GBM. Twenty polymer discs loaded

---

<sup>3</sup> Yang, W., Barth, R.F. and Elleaume, H. Unpublished data.

with cisplatin ( $1 \text{ mg/cm}^2$ ) were placed in the tumor bed. Two to three weeks after surgery, the patients received radiotherapy (60Gy). This combined treatment significantly increased the MST compared to that observed in patients who had received radiotherapy alone (427 *versus* 211 d., respectively) (14).

A variety of systems has been proposed for the treatment of malignant brain tumors to deliver anti-cancer drugs locally in a sustained-released manner (11, 12, 15-18, 20, 30). Our chemotherapy results are in good agreement with those reported by Olivi *et al.* (12) using carboplatin-loaded biodegradable polymers for the treatment of the F98-glioma. They reported that 5% carboplatin-loaded polymer ( $\sim 0.5 \text{ mg}$  of drug), released over 8 to 13d., produced a threefold increase in MeST compared to controls. Systemic administration of carboplatin also significantly prolonged survival, but this was less effective than i.c. delivery (12). Therapeutic efficacy was dose-related with an increasing number of early deaths associated with escalating doses of the drug up to  $0.5 \text{ mg}$  (12). In our study, the amount of carboplatin administered ( $72 \mu\text{g}$ ) was well below that used by Olivi *et al.* (12); it was well tolerated and resulted in 11% to 23% long-term survivors for chemotherapy alone (Tables 1 and 2). Carson *et al.* have reported that the infusion of carboplatin over a 7-day period with ALZET<sup>TM</sup> pumps at a dose of  $0.1 \text{ mg}$  doubled the MST of Fischer rats bearing brainstem implants of either the F98-glioma or 9L gliosarcoma (16). It is noteworthy that the brainstem was not damaged by direct infusion of  $200 \mu\text{L}$  of carboplatin ( $0.5 \text{ mg/mL}$ ) at a flow rate of  $1 \mu\text{L/h}$ , and that there was no neurotoxicity until a lethal dose ( $\geq 1.0 \text{ mg/mL}$ ) was administered (18). Carboplatin also has been infused into the brainstem of monkeys over extended periods of time, and dose-dependent neurotoxicity only was observed with doses  $>400 \mu\text{g}$  (22, 31). Using atomic absorption spectroscopy, Guarnieri *et al.* have mapped the distribution of platinum after i.c. infusion of carboplatin using ALZET<sup>TM</sup> pumps into F98 glioma-bearing rats, with delivery parameters similar to those that we used. Platinum

concentrations were maximal in brain sections corresponding to the infusion site with diminished amounts (1 to 5 $\mu$ g/g tissue) in sections that were 3mm from the point of infusion (17, 30). However, this distribution pattern was observed in only half of the brains infused with rigid catheters such as the ones we have used. In contrast, the use of flexible catheters resulted in the expected drug distribution in all of the rats, in both normal and tumor-bearing animals. It was suggested that rigid catheters might result in backflow of the drug into the subdural space along the catheter path (17).

In conclusion, our data have demonstrated that intratumoral infusion of carboplatin, followed by either synchrotron, as in the present study, or as previously reported (6) 6MV LINAC photon irradiation, is highly effective for the treatment of F98 glioma bearing rats. Studies to further improve this chemo-radiotherapeutic approach are in progress and will focus on further optimizing the drug delivery and radiation parameters, and on striking a balance between neurotoxicity and therapeutic efficacy.

## References

1. Behin A, Hoang-Xuan K, Carpentier AF, *et al.* Primary brain tumours in adults. *Lancet* 2003;361:323-331.
2. Stupp R, Hegi ME, Gilbert MR, *et al.* Chemoradiotherapy in malignant glioma: standard of care and future directions. *Journal of Clinical Oncology* 2007;25:4127-4136.
3. Barth RF, Coderre JA, Vicente MG, *et al.* Boron neutron capture therapy of cancer: current status and future prospects. *Clinical Cancer Research* 2005;11:3987-4002.
4. Adam JF, Joubert A, Biston MC, *et al.* Prolonged survival of Fischer rats bearing F98 glioma after iodine-enhanced synchrotron stereotactic radiotherapy. *International Journal of Radiation Oncology, Biology, Physics* 2006;64:603-611.
5. Biston MC, Joubert A, Adam JF, *et al.* Cure of Fisher rats bearing radioresistant F98 glioma treated with cis-platinum and irradiated with monochromatic synchrotron X-rays. *Cancer Research* 2004;64:2317-2323.
6. Rousseau J, Boudou C, Barth RF, *et al.* Enhanced survival and cure of F98 glioma-bearing rats following intracerebral delivery of carboplatin in combination with photon irradiation. *Clinical Cancer Research* 2007;13:5195-5201.
7. Kelland L. The resurgence of platinum-based cancer chemotherapy. *Nature Reviews. Cancer* 2007;7:573-584.
8. Nias AH. Radiation and platinum drug interaction. *International Journal of Radiation Biology and Related Studies in Physics, Chemistry and Medicine* 1985;48:297-314.
9. Muldoon LL, Soussain C, Jahnke K, *et al.* Chemotherapy delivery issues in central nervous system malignancy: a reality check. *Journal of Clinical Oncology* 2007;25:2295-2305.

10. Bobo RH, Laske DW, Akbasak A, *et al.* Convection-enhanced delivery of macromolecules in the brain. *Proceedings of the National Academy of Sciences of the United States of America* 1994;91:2076-2080.
11. Brem H. Polymers to treat brain tumours. *Biomaterials* 1990;11:699-701.
12. Olivi A, Ewend MG, Utsuki T, *et al.* Interstitial delivery of carboplatin via biodegradable polymers is effective against experimental glioma in the rat. *Cancer Chemotherapy and Pharmacology* 1996;39:90-96.
13. Emerich DF, Winn SR, Snodgrass P, *et al.* Injectable chemotherapeutic microspheres and glioma II: enhanced survival following implantation into deep inoperable tumors. *Pharm Res* 2000;17:776-781.
14. Sheleg SV, Korotkevich EA, Zhavrid EA, *et al.* Local chemotherapy with cisplatin-depot for glioblastoma multiforme. *J Neurooncol* 2002;60:53-59.
15. Yapp DT, Lloyd DK, Zhu J, *et al.* Cisplatin delivery by biodegradable polymer implant is superior to systemic delivery by osmotic pump or i.p. injection in tumor-bearing mice. *Anticancer Drugs* 1998;9:791-796.
16. Carson BS, Sr., Wu Q, Tyler B, *et al.* New approach to tumor therapy for inoperable areas of the brain: chronic intraparenchymal drug delivery. *Journal of Neuro-Oncology* 2002;60:151-158.
17. Guarnieri M, Carson BS, Khan A, *et al.* Flexible versus rigid catheters for chronic administration of exogenous agents into central nervous system tissues. *Journal of Neuroscience Methods* 2005;144:147-152.
18. Wu Q, Guarnieri M, Tyler B, *et al.* Section on tumors: Young Investigator Award: Local release of carboplatin via an Alzet mini-osmotic pump prolongs survival in a rat brainstem tumor model. *Clinical Neurosurgery* 2004;51:332-339.

19. Knox RJ, Friedlos F, Lydall DA, *et al.* Mechanism of cytotoxicity of anticancer platinum drugs: evidence that cis-diamminedichloroplatinum(II) and cis-diammine-(1,1-cyclobutanedicarboxylato)platinum(II) differ only in the kinetics of their interaction with DNA. *Cancer Research* 1986;46:1972-1979.
20. Olivi A, Gilbert M, Duncan KL, *et al.* Direct delivery of platinum-based antineoplastics to the central nervous system: a toxicity and ultrastructural study. *Cancer Chemotherapy and Pharmacology* 1993;31:449-454.
21. Degen JW, Walbridge S, Vortmeyer AO, *et al.* Safety and efficacy of convection-enhanced delivery of gemcitabine or carboplatin in a malignant glioma model in rats. *Journal of Neurosurgery* 2003;99:893-898.
22. Strege RJ, Liu YJ, Kiely A, *et al.* Toxicity and cerebrospinal fluid levels of carboplatin chronically infused into the brainstem of a primate. *Journal of Neuro-Oncology* 2004;67:327-334.
23. Tzeng JJ, Barth RF, Orosz CG, *et al.* Phenotype and functional activity of tumor-infiltrating lymphocytes isolated from immunogenic and nonimmunogenic rat brain tumors. *Cancer Res* 1991;51:2373-2378.
24. Barth RF, Yang W, Rotaru JH, *et al.* Boron neutron capture therapy of brain tumors: enhanced survival and cure following blood-brain barrier disruption and intracarotid injection of sodium borocaptate and boronophenylalanine. *Int J Radiat Oncol Biol Phys* 2000;47:209-218.
25. Elleaume H, Charvet AM, Berkvens P, *et al.* Instrumentation of the ESRF medical imaging facility. *Nuclear Instruments and Methods in Physics Research Section A* 1999;428:513-527.
26. Klein JP, Moeschberger ML. Survival analysis techniques for censored and truncated data. 2nd ed. New York: Springer; 2003.

27. Perry A, Schmidt RE. Cancer therapy-associated CNS neuropathology: an update and review of the literature. *Acta Neuropathol* 2006;111:197-212.
28. Yang W, Barth RF, Wu G, *et al.* Development of a syngeneic rat brain tumor model expressing EGFRvIII and its use for molecular targeting studies with monoclonal antibody L8A4. *Clin Cancer Res* 2005;11:341-350.
29. Bouvier G, Penn RD, Kroin JS, *et al.* Direct delivery of medication into a brain tumor through multiple chronically implanted catheters. *Neurosurgery* 1987;20:286-291.
30. Khan A, Jallo GI, Liu YJ, *et al.* Infusion rates and drug distribution in brain tumor models in rats. *Journal of Neurosurgery* 2005;102:53-58.
31. Storm PB, Clatterbuck RE, Liu YJ, *et al.* A surgical technique for safely placing a drug delivery catheter into the pons of primates: preliminary results of carboplatin infusion. *Neurosurgery* 2003;52:1169-1176; discussion 1176-1167.



## Figure Legends

Fig. 1. Kaplan-Meier survival curves for F98 glioma-bearing rats after chemotherapy or radiotherapy. The origin of the x-axis corresponds to tumor implantation. Group 1: untreated ( $\times$ ), Group 2: carboplatin ( $\blacktriangle$ ), Group 3: X-irradiation alone (-); and Group 4: 5% dextrose (vehicle) followed by X-irradiation ( $\square$ ). The survivals of all treatment groups were significantly different from the untreated controls ( $p < 0.001$ ). The survival of the animals that received 5% dextrose infusion (excipient), followed by X-irradiation was not significantly different ( $p = 0.51$ ) from animals that received X-irradiation alone.

Fig. 2. Kaplan-Meier survival curves for F98 glioma-bearing rats after chemo-radiotherapy. The origin of the x-axis corresponds to tumor implantation. Group 5: untreated ( $\times$ ); Group 6: X-irradiation (-); Group 7: carboplatin alone ( $\blacktriangle$ ), or Group 8: in combination with X-irradiation ( $\triangle$ ). The survivals of all treatment groups were significantly different from the untreated controls ( $p < 0.0015$ ). The survival of the animals that received carboplatin, followed by X-irradiation was significantly different from X-irradiated animals ( $p = 0.0014$ ) or those that received carboplatin alone ( $p = 0.0472$ ).

Fig. 3. Histology. **A.** F98 glioma in an untreated rat. The tumor invaded the gray and white matter and extended into the leptomeningeal space. **B.** Brain of an animal that received i.c. carboplatin. No residual tumor was identified. There was a microscopic porencephalic cyst with a light scattering of lymphocytes and macrophages along the wall of the cyst. **C.** and **D.** Brains of two rats that received i.c. carboplatin, combined with

X-irradiation. No residual tumor was identified. There were microscopic porencephalic cysts with focal accumulations of macrophages with some intracellular dystrophic deposits of calcium, and occasional giant cells. (200X).

## Table legends

Table 1. Survival times of F98 glioma-bearing rats following chemotherapy or radiotherapy alone.

Table 2. Survival times of F98 glioma-bearing rats following chemotherapy with or without X-irradiation.

Figure 1

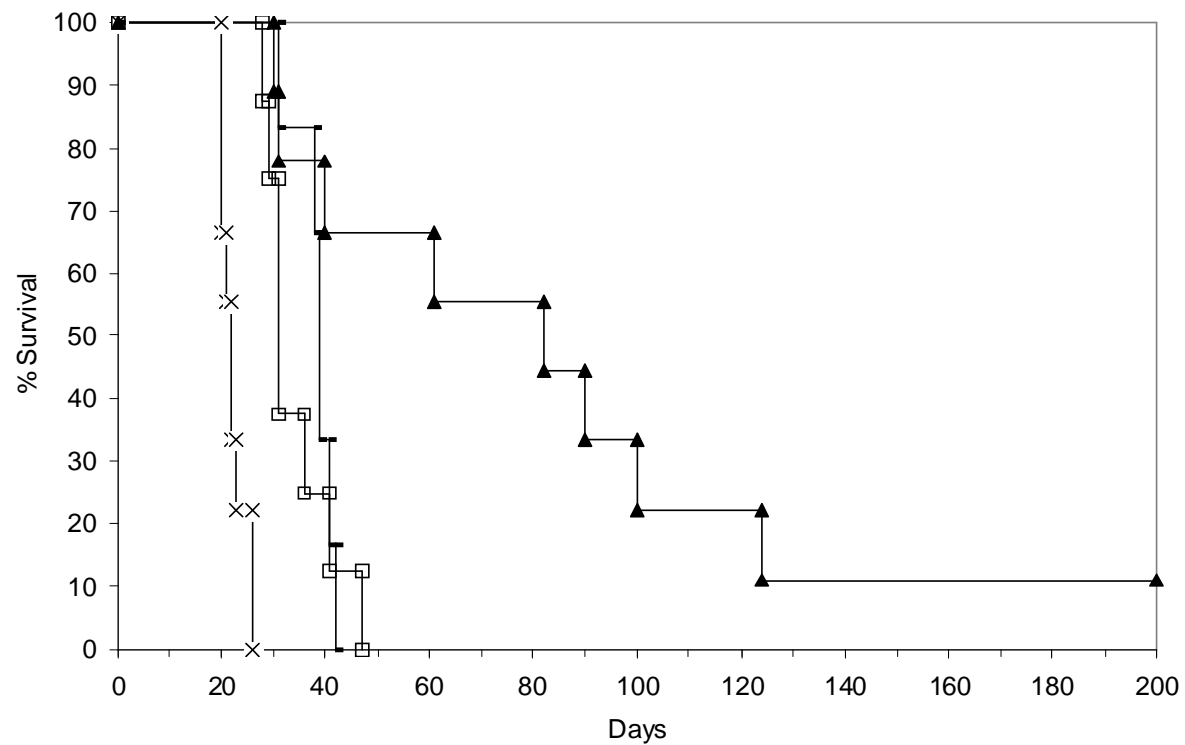


Figure 2

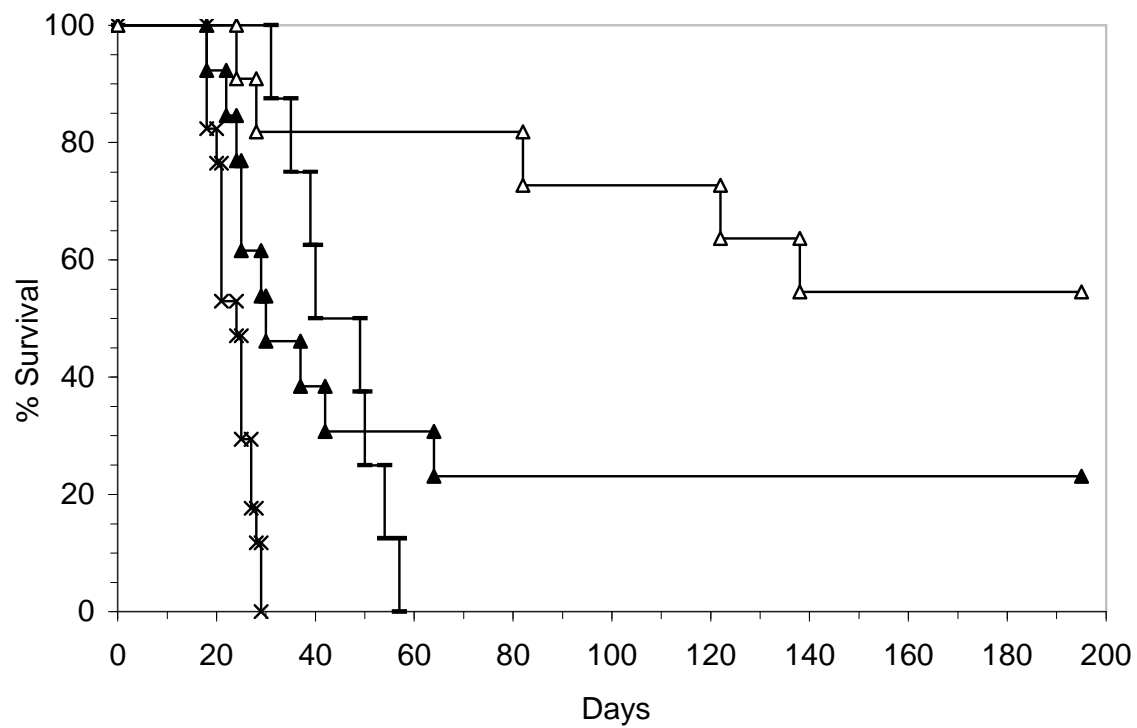


Figure 3

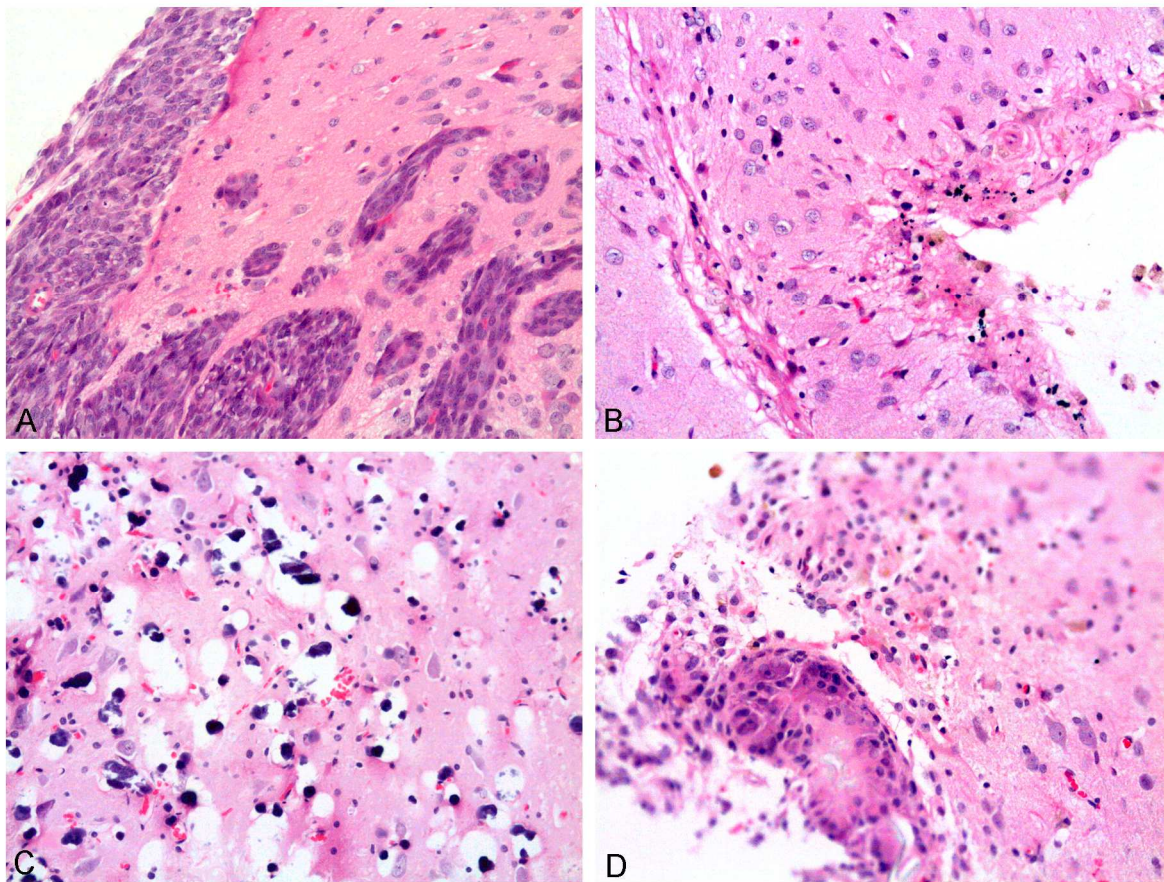


Table 1. Survival times of F98 glioma-bearing rats following chemotherapy or radiotherapy alone.

Group number, treatment	Number of rats	Survival time (days)			% Increased life span		Statistical analysis of survival
		Range	Mean $\pm$ SE	Median	Mean	Median	log-rank test p-value
Group 1, Untreated controls	9	20-26	22 $\pm$ 1	22	-	-	
Group 2, Chemotherapy	9	30-200 (1) <sup>§</sup>	84 $\pm$ 18 <sup>¶</sup>	82	279 <sup>¶</sup>	273	<0.001 <i>versus</i> Group 1 (Untreated control)
Group 3, Radiotherapy	6	31-42	38 $\pm$ 2	39	72	77	<0.001 <i>versus</i> Group 1 (Untreated control)
Group 4, Dextrose + Radiotherapy	8	28-47	34 $\pm$ 2	31	54	41	<0.001 <i>versus</i> Group 1 (Untreated control) p = 0.51 <i>versus</i> Group 3 (Radiotherapy)

<sup>§</sup> Day 200 was considered as the endpoint of the experiment. Rats still alive at this time were euthanized. The number in parenthesis indicates the number of rats surviving > 200 days (censored data).

<sup>¶</sup> Indicates that the mean or the % increased life span was based on censored data.

Table 2. Survival times of F98 glioma-bearing rats following infusion of carboplatin with or without X-irradiation

Group number, Treatment	Number of rats/group	Survival time (days)			% Increased life span		Statistical analysis of survival
		Range	Mean $\pm$ SE	Median	Mean	Median	log-rank test p-value
Group 5, Untreated controls	17	18-29	23 $\pm$ 1	24	-	-	-
Group 6, Chemotherapy	13	18-195 (3) <sup>§</sup>	69 $\pm$ 20 <sup>¶</sup>	30	197 <sup>¶</sup>	25	p<0.001 <i>versus</i> Group 5 (Untreated control)
Group 7, Radiotherapy	8	31-57	44 $\pm$ 3	45	90	85	p<0.001 <i>versus</i> Group 5 (Untreated control)
Group 8, Chemotherapy	11	24-195 (6) <sup>§</sup>	142 $\pm$ 21 <sup>¶</sup>	195 <sup>¶</sup>	509 <sup>¶</sup>	713 <sup>¶</sup>	p<0.001 <i>versus</i> Group 5 (Untreated control) p=0.0472 <i>versus</i> Group 6 (Chemotherapy)

<sup>§</sup> Day 195 was the endpoint of the experiment. Rats still alive at this time were euthanized. The number in parenthesis indicates the number of rats surviving > 195 days. (censored data).

<sup>¶</sup> Indicates that the mean, or the median, or the % increased life span, were based on censored data.